



**HAL**  
open science

## **Report on a Case with Moreno-Nishimura-Schmidt Overgrowth Syndrome: A Clinically Delineated Disease Yet of an Unknown Origin!**

Cybel Mehawej, Eliane Chouery, Ghada Al Hage Chehade, Yosra Bejaoui,  
Daniel Mahfoud, Maya Gerges, Valérie Delague, Nady El Hajj, Andre  
Megarbane

### **► To cite this version:**

Cybel Mehawej, Eliane Chouery, Ghada Al Hage Chehade, Yosra Bejaoui, Daniel Mahfoud, et al.. Report on a Case with Moreno-Nishimura-Schmidt Overgrowth Syndrome: A Clinically Delineated Disease Yet of an Unknown Origin!. *Molecular Syndromology*, 2023, 14 (3), pp.219-224. 10.1159/000527215 . hal-04254106

**HAL Id: hal-04254106**

**<https://amu.hal.science/hal-04254106>**

Submitted on 12 Mar 2024

**HAL** is a multi-disciplinary open access archive for the deposit and dissemination of scientific research documents, whether they are published or not. The documents may come from teaching and research institutions in France or abroad, or from public or private research centers.

L'archive ouverte pluridisciplinaire **HAL**, est destinée au dépôt et à la diffusion de documents scientifiques de niveau recherche, publiés ou non, émanant des établissements d'enseignement et de recherche français ou étrangers, des laboratoires publics ou privés.

1 **Report on a case with Moreno-Nishimura-Schmidt overgrowth syndrome:**

2 **A clinically delineated disease, yet of an unknown origin!**

3 Cybel Mehawej<sup>1</sup>, Eliane Chouery<sup>1</sup>, Ghada Al Hage Chehade<sup>2,3</sup>, Yosra Bejaoui<sup>4</sup>, Daniel Mahfoud<sup>5</sup>,  
4 Maya Gerges<sup>6</sup>, Valérie Delague<sup>7</sup>, Nady El Hajj<sup>4</sup>, Andre Megarbane<sup>1,8</sup>

5  
6 1 Department of Human Genetics, Gilbert and Rose-Marie Chagoury School of Medicine,  
7 Lebanese American University, Byblos, Lebanon.

8 2 Pediatric endocrinology and diabetology, pediatrics department, Hammoud hospital  
9 university medical center, Saida, Lebanon

10 3 Pediatric endocrinology and diabetology, pediatric division, Saint George hospital  
11 university medical center, Beirut, Lebanon

12 4 College of Health and Life Sciences, Hamad Bin Khalifa University, Qatar Foundation,  
13 Education City, Doha P.O. Box 34110, Qatar.

14 5 Department of Radiology, Gilbert and Rose-Marie Ghagoury School of Medicine,  
15 Lebanese American University, Byblos, Lebanon.

16 6 Genetic laboratory, American University of Science and Technology, Lebanon.

17 7 Aix Marseille Univ, Inserm, MMG, U 1251, Institut Marseille Maladies Rares (MarMaRa),  
18 Marseille, France.

19 8 Institut Jérôme Lejeune, Paris, France.

20 Running title: Methylation differences in Moreno-Nishimura-Schmidt syndrome

21  
22 **Corresponding Author:**

23 Andre Megarbane, MD, PhD, Department of Human Genetics, Gilbert and Rose-Marie Chagoury  
24 School of Medicine, Lebanese American University, Byblos, Lebanon. E-mail:  
25 [andre.megarbane@lau.edu.lb](mailto:andre.megarbane@lau.edu.lb)

26  
27 Number of Tables: 1

28 Number of Figures: 2

29 Supplementary Tables: 1

30 Word count: 1546.

31 Keywords: rare syndrome, Moreno-Nishimira-Schmidt overgrowth syndrome, clinical genetics,  
32 epigenetics.

### 33 Established Facts and Novel Insights

#### Established Facts

- Overgrowth syndromes are a heterogeneous group of genetic disorders characterized by excessive growth often accompanied by additional clinical features
- A complex interplay of genetic, epigenetic, and/or hormonal factors can contribute to overgrowth syndromes.
- Moreno-Nishimura–Schmidt overgrowth syndrome is a very rare overgrowth syndrome that is clinically delineated but molecularly uncharacterized yet.

34

#### Novel Insights

- A Lebanese patient with Moreno-Nishimura–Schmidt syndrome presenting with osteoporosis and mild intellectual disability is reported
- CGH array analysis was performed for the first time on a patient with M-N-S but failed to reveal the causative genetic aberration
- Epigenetic studies revealed a difference in the methylation status of several CpG sites in the patient compared to controls, with methyltransferase activity showing the most significant enrichment

35 **Abstract**

36 ***Introduction***

37 Overgrowth syndromes are a heterogeneous group of genetic disorders characterized by excessive  
38 growth often accompanied by additional clinical features, such as facial dysmorphism, hormonal  
39 imbalances, cognitive impairment and increased risk for neoplasia. Moreno-Nishimura–Schmidt  
40 (M-N-S) overgrowth syndrome is a very rare overgrowth syndrome characterized by severe pre-  
41 and post- natal overgrowth, dysmorphic facial features, kyphoscoliosis, large hands and feet,  
42 inguinal hernia and distinctive skeletal features. The clinical and radiologic features of the disorder  
43 have been well delineated; yet, its molecular pathogenesis remains unclear.

44 ***Case presentation***

45 We report on a Lebanese boy with M-N-S syndrome, whose clinical manifestations were  
46 compared with those of previously reported 5 affected individuals. Whole exome sequencing  
47 combined with comparative genome hybridization analysis failed to delineate the molecular basis  
48 of the phenotype. However, epigenetic studies revealed a different methylation status of several  
49 CpG sites between him and healthy controls, with methyltransferase activity showing the most  
50 significant enrichment.

51 ***Conclusion***

52 An additional case of M-N-S syndrome recapitulated the clinical and radiological  
53 manifestations described in the previous reports. The data in the epigenetic studies implicated that  
54 abnormal methylations might play an essential role in development of the disease phenotype.  
55 However, additional studies in a clinically homogeneous cohort of patients are crucial to confirm  
56 this hypothesis.

57

58

59 **Introduction**

60 Overgrowth syndromes (OGS) are a heterogeneous group of disorders characterized by  
61 increased growth parameters in addition to other variable features including facial dysmorphism,  
62 life-threatening hypoglycemia, hormonal imbalances, cognitive impairment and increased risk for  
63 neoplasia [Lapunzina, 2005; Lacerda et al., 2014; Manor and Lalani, 2020]. Overgrowth can be  
64 generalized, leading to an increase in overall growth parameters or localized/partial, affecting one  
65 or few body organs/segments [Welch, 2015; Kamien et al., 2018]. Some OGS present with prenatal  
66 overgrowth features that can be postnatally progressive, while others with postnatal overgrowth  
67 that manifests in infancy and childhood or even in adolescence [Manor and Lalani, 2020].

68 A complex interplay of genetic, epigenetic, and/or hormonal factors can contribute to the disease  
69 [Cytrynbaum et al., 2019; Manor and Lalani, 2020; Mazziotti et al., 2022]. Constitutional and  
70 somatic aberrations of single genes are involved in global and localized overgrowth disorders,  
71 respectively. In addition, genomic imprinting abnormalities are the third mechanism of growth  
72 dysregulation [Tatton-Brown and Weksberg, 2013].

73 Among more than 15 different OGS that have been recognized to date, Moreno-Nishimura–  
74 Schmidt (M-N-S) overgrowth syndrome, also known as endochondral gigantism or metaphyseal  
75 under modelling spondylar dysplasia and overgrowth (MIM#608811), is a rare generalized OGS.  
76 The disorder is characterized by severe pre- and post-natal overgrowth, facial dysmorphism,  
77 kyphoscoliosis and skeletal features, including hyperostosis of the skull base, spondylar dysplasia  
78 and metaphyseal broadening [Moreno et al., 1974; Nishimura et al., 2004; Schmidt et al., 2007;  
79 Bonafe et al., 2015]. To date, 5 affected individuals have been reported [Moreno et al., 1974;  
80 Nishimura et al., 2004; Sadeghi-Nejad and Karlin, 2005; Schmidt et al., 2007; Handa et al., 2017].

81 Although the clinical and radiologic features of the disease have been well delineated, its molecular  
82 basis and pathogenesis remain elusive.

83 We report here on a Lebanese patient with M-N-S syndrome, including his thorough clinical  
84 description and radiological manifestations with comparison with those previously reported and  
85 epigenetic abnormalities on molecular examinations.

### 86 **Case report**

87 The patient was a Lebanese boy who was born at term to his healthy unrelated parents. Birth weight  
88 was 5600g; length 61 cm; and head circumference (OFC) 38,3 cm (all largely above the  
89 97th percentile). He also showed an abnormal spinal curvature and hypotonia. Echocardiography  
90 revealed a small ostium secundum atrial septal defect. His developmental milestones were delayed:  
91 he sat alone at age 9 months and walked unaided at 19 months. He was clumsy even in gross  
92 movement. The anterior fontanelle was open in infancy, and closed at 24 months. He showed  
93 progressive kyphoscoliosis, which was managed with orthotic treatment for 4-5 months at age 2  
94 years and then surgery 3 times; however, the interventions were not beneficial. At age 3 years,  
95 bilateral inguinal hernias were repaired. He also reported to receive bisphosphonates for  
96 osteoporosis. Growth hormone suppression test using oral glucose showed a nadir of growth  
97 hormone at 0.5 ng/ml and low IGF1 (post-load: 13.5 ng/ml; pre-load: 8.5 ng/ml; normal value:  
98 26.8-134 ng/ml). We first met him at the age of 4 years (Fig.1). He was very pleasant; and  
99 understood the orders, but responded to questions with simple words but without sentences. His  
100 voice was hoarse. His standing posture and gait were clumsy. Height was 138 cm; weight 40 kgs,  
101 and OFC 57.7 cm (all above the 97th percentile). He showed macrocephaly and facial  
102 dysmorphism, including a sloped forehead, prominent supra-orbital ridges, deep-set eyes, large  
103 and prominent nose, large ears, thin upper lip, pointed chin, and relatively small jaw. He looked

104 more senile than his chronological age. The skin was soft and translucent, but not of  
105 hyperextensibility or fragility. Pectus carinatum and mild cutis laxa of the lower abdomen with  
106 three small café-au-lait spots were seen. The hands were large measuring 20,5 cm  
107 (>>97th percentile) and feet were large as well. Flexion deformity of the large joints was noted,  
108 and mild contracture of the elbow and knee joints was evident. The testis was not palpable, and  
109 bilateral inguinal hernia were present. The neurological and ophthalmological examinations were  
110 normal. Concentrations of luteinizing hormone, follicle stimulating hormone, testosterone,  
111 estradiol, and esterone were all in the normal prepubertal range. His mother was 155 cm and father  
112 170 cm tall.

113 Full skeletal survey showed diffuse bone demineralization, hypertrophy of the sphenoid bone  
114 leading to an abnormal appearance of the clivus and poorly identified sella turcica, an anomalous  
115 craniovertebral junction (atlanto-occipital impaction and unfused odontoid), cervical rib of the left  
116 side, severe thoracolumbar, poorly defined acetabular rim with rounded acetabular roof, coxa  
117 valga, enlargement of the metaphysis and epiphysis of the long bones with otherwise preserved  
118 shape (Fig.1). At 3.5 years old, the bone age of the patient was estimated to be 6 years according  
119 to Greulich and Pyle radiographic atlas of skeletal development.

120 The excessive pre- and post-natal overgrowth occurring with the dysmorphic facial features, the  
121 hoarse voice, inguinal hernias, joints abnormalities and distinctive skeletal features, such as  
122 metaphyseal widening and spondylar dysplasia, prompted the diagnosis of M-N-S syndrome.

123 Whole Exome Sequencing revealed a heterozygous variant of unknown significance in *IGF2*  
124 (NM\_000612: c.412C>T: p.R138W), which was initially considered as a candidate because of  
125 previous reports on overexpression of *IGF2* in Beckwith-Wiedemann syndrome[Murrell et al.,  
126 2004; Chao and D'Amore, 2008]. Nevertheless, segregation analysis excluded the hypothesis, as

127 the paternally inherited variant is also carried by two unaffected siblings. A Comparative Genome  
128 Hybridization (CGH) analysis failed to detect any relevant chromosomal aberration. His genome-  
129 wide DNA methylation patterns were compared with those of 11 healthy controls, including the  
130 gender matched healthy brother who is around 1 year older. CpG sites were filtered for those with  
131 10%  $\beta$  methylation difference (difference  $> 0.1$  or  $< -0.1$ ). Following Bonferroni correction, 476  
132 differentially methylated sites were detected between the proband and controls (Fig. 2). None of  
133 these was in the genes related to known overgrowth syndromes. Gene Ontology (GO) enrichment  
134 for these sites revealed enrichment for 11 GO terms with methyltransferase activity showing the  
135 most significant enrichment (Suppl. Table 1). Gene ontology enrichment analysis determines  
136 whether a particular set of genes is enriched for certain classes of gene functions classified as GO  
137 terms. This analysis revealed the differentially methylated gene PR/SET Domain 10 (*PRDM10*) to  
138 be related to methyltransferase activity as part of GO term 0008168 (Fig. 2b). We further examined  
139 DNA methylation EPIC probes overlapping the imprinting differentially methylated regions  
140 (DMR). A single significant CpG site in the GNAS DMR was hypomethylated in the patient ( $\beta$   
141 methylation = 0.135; mean  $\beta$  methylation of controls = 0.246),  $\beta$  methylation of his healthy sibling  
142 = 0.249) (Fig. 2b). However, the approach used does not allow correction for co-variables including  
143 blood cell composition which is one of the limitations of this analysis.

144

145

## 146 **Discussion**

147 Here is an additional report on M-N-S syndrome in a Lebanese boy presenting with, congenital  
148 overgrowth, dysmorphic facial features, deformity of the large joints, inguinal hernias,  
149 osteoporosis, bone abnormalities, slightly low intellectual abilities, and decreased IGF1. We



150 summarized his manifestations and those of previously reported affected individuals (Table 1). We  
151 ascertained that decreased bone density and mild intellectual disability were syndromic  
152 components. The former was previously reported in two patients  
153 [Sadeghi-Nejad and Karlin, 2005; Schmidt et al., 2007], and the latter in two as well [Nishimura  
154 et al., 2004; Schmidt et al., 2007].

155 WES and CGH analyses did not reveal any causative variant or chromosome derangement,  
156 respectively, as with the case reported by Handa and colleagues [Handa et al., 2017]. However, a  
157 DNA methylation analysis revealed 476 significant CpG sites, which have the most significant  
158 GO term enrichment for methyltransferase activities (Suppl. Table 1). Interestingly,  
159 methyltransferases have been widely linked to known OGS; including NSD1 involved in Sotos  
160 syndrome, EZH2 in Weaver syndrome, DNMT3A in an OGS with facial dysmorphism and  
161 intellectual disability [Tatton-Brown et al., 2014]. The probable methylation abnormalities may be  
162 a clue to the pathogenesis of MNS syndrome. The link between the M-N-S syndrome and  
163 methyltransferases needs to be further investigated and tested in a clinically homogeneous cohort  
164 of affected individuals. However, this is extremely challenging due to the rarity of this entity.  
165 Therefore, additional reports and methylation studies are required to reach the goal.

166

167

168

169 **Statements**

170 **Acknowledgments**

171 We thank the family for the full cooperation.

172

173 **Statement of Ethics:**

174 Approval to conduct the study was obtained from the IRB of the Lebanese American University,  
175 Lebanon. Written informed consent for analysis, and data and photo publication was obtained from  
176 the family in compliance with national ethics regulation.

#### 177 **Conflict of Interest Statement**

178 Authors declare no conflicts of interests.

#### 179 **Funding Sources**

180 This study did not receive any funding.

#### 181 **Authors' contributions**

182 Cybel Mehawej, Eliane Chouery and Andre Megarbane designed the study, interpreted data and  
183 wrote the manuscript.

184 Nady El Hajj and Yosra Bejaoui performed the epigenetic studies.

185 Valérie Delague performed WES.

186 Maya Gerges contributed to technical work.

187 Ghada Al Hage Chehade and Daniel Mahfoud contributed to the patient's clinical evaluation.

188 All authors approved the manuscript.

#### 189 **Data Availability Statement:**

190 Data is available from the corresponding author upon request

191

#### 192 **References**

193 Bonafe L, Cormier-Daire V, Hall C, Lachman R, Mortier G, Mundlos S, Nishimura G, Sangiorgi  
194 L, Savarirayan R, Silience D, Spranger J, Superti-Furga A, Warman M, Unger S. 2015.  
195 Nosology and classification of genetic skeletal disorders: 2015 revision. *Am. J. Med.*  
196 *Genet. A.* 167A: 2869–2892.

197 Chao W, D'Amore PA. 2008. IGF2: epigenetic regulation and role in development and disease.  
198 *Cytokine Growth Factor Rev.* 19: 111–120.

199 Cytrynbaum C, Choufani S, Weksberg R. 2019. Epigenetic signatures in overgrowth syndromes:  
200 Translational opportunities. *Am. J. Med. Genet. C Semin. Med. Genet.* 181: 491–501.

201 Handa A, Muroya K, Ishii T, Nishimura G. 2017. Additional report on Moreno-Nishimura-  
202 Schmidt overgrowth syndrome. *Am. J. Med. Genet. A.* 173: 2834–2837.

203 Kamien B, Ronan A, Poke G, Sinnerbrink I, Baynam G, Ward M, Gibson WT, Dudding-Byth T,  
204 Scott RJ. 2018. A Clinical Review of Generalized Overgrowth Syndromes in the Era of  
205 Massively Parallel Sequencing. *Mol. Syndromol.* 9: 70–82.

- 206 Lacerda L da S, Alves UD, Zanier JFC, Machado DC, Camilo GB, Lopes AJ. 2014. Differential  
207 diagnoses of overgrowth syndromes: the most important clinical and radiological disease  
208 manifestations. *Radiol. Res. Pract.* 2014: 947451.
- 209 Lapunzina P. 2005. Risk of tumorigenesis in overgrowth syndromes: a comprehensive review.  
210 *Am. J. Med. Genet. C Semin. Med. Genet.* 137C: 53–71.
- 211 Luscan A, Laurendeau I, Malan V, Francannet C, Odent S, Giuliano F, Lacombe D, Touraine R,  
212 Vidaud M, Pasmant E, Cormier-Daire V. 2014. Mutations in SETD2 cause a novel  
213 overgrowth condition. *J. Med. Genet.* 51: 512–517.
- 214 Manor J, Lalani SR. 2020. Overgrowth Syndromes-Evaluation, Diagnosis, and Management.  
215 *Front. Pediatr.* 8: 574857.
- 216 Mazziotti G, Lania AG, Canalis E. 2022. Skeletal disorders associated with the growth hormone-  
217 insulin-like growth factor 1 axis. *Nat. Rev. Endocrinol.* 18: 353–365.
- 218 Moreno HC, Zachai EH, Kaufmann HJ, Mellmann WJ. 1974. Case 18. Syndrome Identification  
219 2: 22–25.
- 220 Murrell A, Heeson S, Cooper WN, Douglas E, Apostolidou S, Moore GE, Maher ER, Reik W.  
221 2004. An association between variants in the IGF2 gene and Beckwith-Wiedemann  
222 syndrome: interaction between genotype and epigenotype. *Hum. Mol. Genet.* 13: 247–  
223 255.
- 224 Nishimura G, Hasegawa T, Kinoshita E, Tanaka Y, Kurosawa K, Yoshimoto M. 2004. Newly  
225 recognized syndrome of metaphyseal undermodeling, spondylar dysplasia, and  
226 overgrowth: report of two adolescents and a child. *Am. J. Med. Genet. A.* 128A: 204–  
227 208.
- 228 Sadeghi-Nejad A, Karlin LI. 2005. A provisionally unique syndrome of macrosomia, bone  
229 overgrowth, macrocephaly, and tall stature. *Am. J. Med. Genet. A.* 134: 443–446.
- 230 Schmidt H, Kammer B, Grasser M, Enders A, Rost I, Kiess W. 2007. Endochondral gigantism: a  
231 newly recognized skeletal dysplasia with pre- and postnatal overgrowth and endocrine  
232 abnormalities. *Am. J. Med. Genet. A.* 143A: 1868–1875.
- 233 Tatton-Brown K, Seal S, Ruark E, Harmer J, Ramsay E, Del Vecchio Duarte S, Zachariou A,  
234 Hanks S, O'Brien E, Aksglaede L, Baralle D, Dabir T, Gener B, Goudie D, Homfray T,  
235 Kumar A, Pilz DT, Selicorni A, Temple IK, Van Maldergem L, Yachelevich N,  
236 Childhood Overgrowth Consortium, van Montfort R, Rahman N. 2014. Mutations in the  
237 DNA methyltransferase gene DNMT3A cause an overgrowth syndrome with intellectual  
238 disability. *Nat. Genet.* 46: 385–388.
- 239 Tatton-Brown K, Weksberg R. 2013. Molecular mechanisms of childhood overgrowth. *Am. J.*  
240 *Med. Genet. C Semin. Med. Genet.* 163C: 71–75.

241 Welch TR. 2015. Localized overgrowth syndromes: something in common. *J. Pediatr.* 166: 783–  
242 787.

243

244

245

246 **Supplementary Data:** Supplementary Document 1: Methods; Supplementary Table 1: Gene  
247 ontology enrichment analysis for the differentially methylated CpG sites in the patient after  
248 adjusting for the number of CpG sites per gene on the Illumina Epic arrays.

249

## 250 **Legends**

251 Fig. 1: Photographs of the patient at age 4 showing the dysmorphic facial features and the skeletal  
252 and joints abnormalities; and X-rays at age 3 showing a diffuse decrease in bone mineralization;  
253 Abnormal appearance of the atlanto-occipital joint; Severe scoliotic deformity of the  
254 thoracolumbar spine; and epiphyso-metaphyseal enlargement of the femur.

255 Fig. 2: a. Volcano plot representing  $-\log_{10}$  (adj. p-value) against Beta Methylation Difference  
256 when comparing DNA methylation in the patient vs controls. The significant differentially  
257 methylated sites following Bonferroni correction with a beta methylation difference  $> 0.1$  (10%  
258 methylation) in the patient are displayed in red (hypermethylated) whereas CpG sites with a beta  
259 methylation difference  $< -0.1$  are highlighted in green (hypomethylated) b. Boxplots showing Beta  
260 methylation values for significant CpG sites in the methyltransferase gene *PRDM10* and in the  
261 imprinted gene *GNAS*.

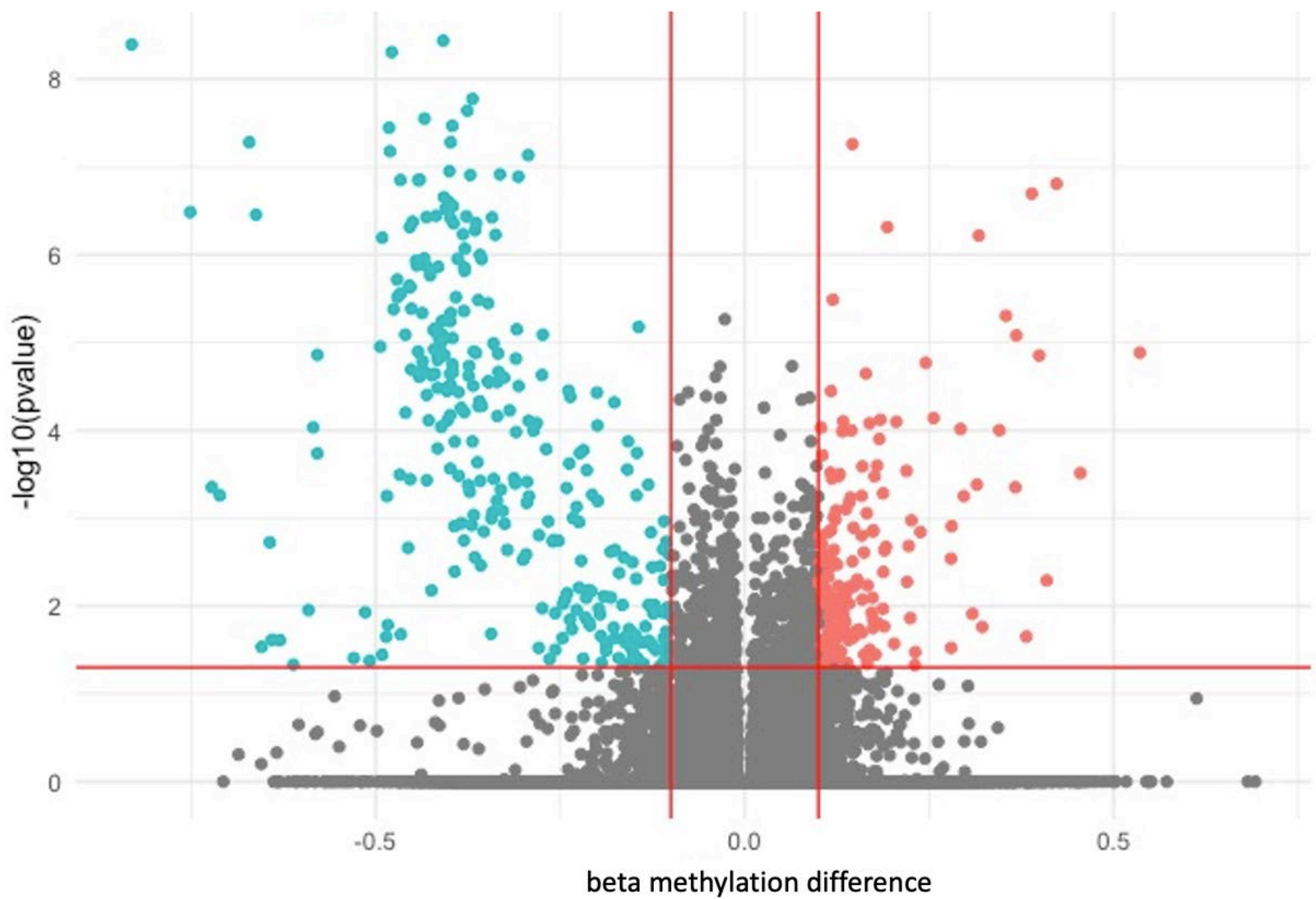
262 Table 1: Clinical features of the reported congenital overgrowth syndrome.

263

264

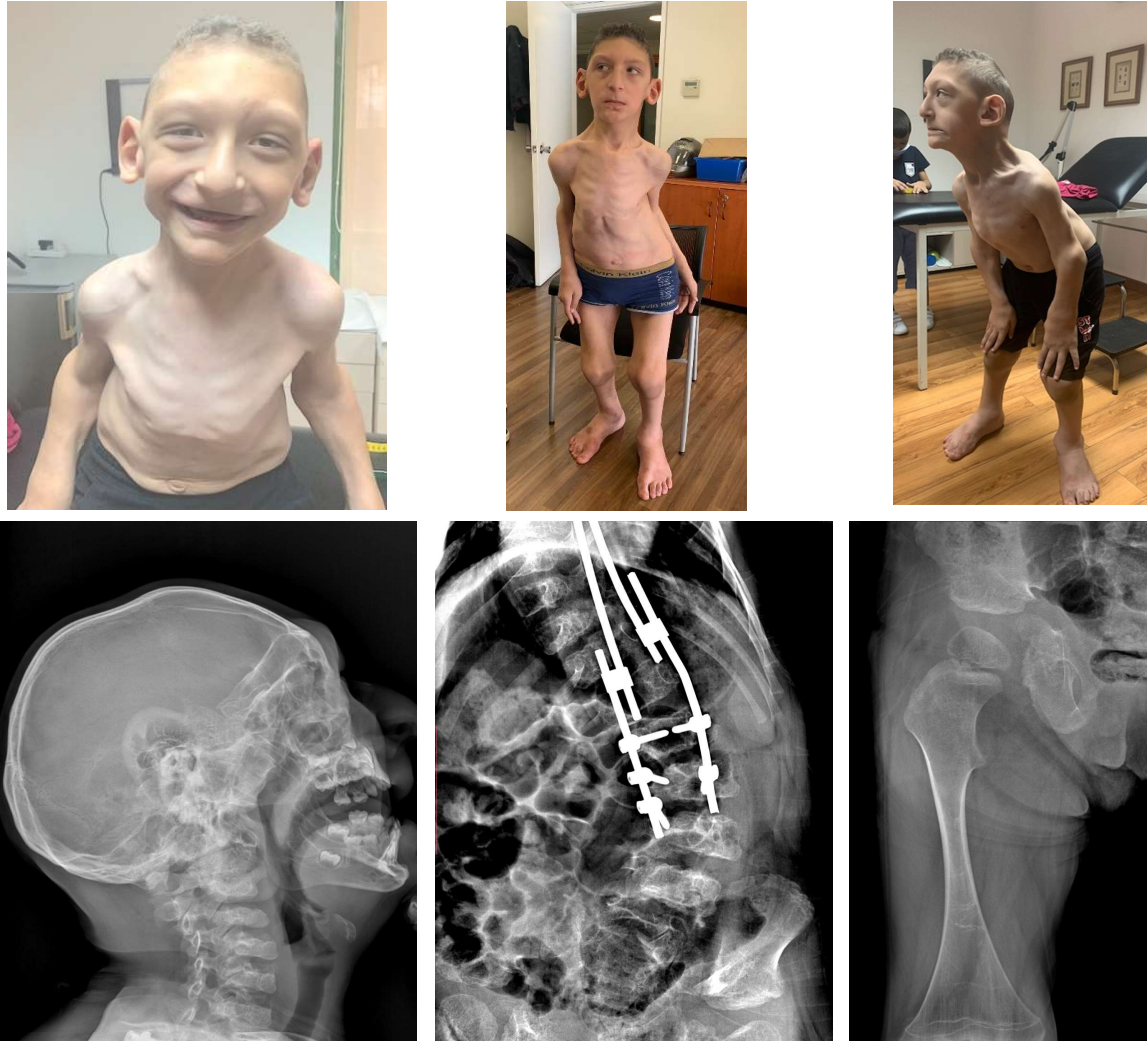

Fig. 1: Photographs of the patient at age 4 showing the dysmorphic facial features and the skeletal and joints abnormalities; and X-rays at age 3 showing a diffuse decrease in bone mineralization; Abnormal appearance of the atlanto-occipital joint; Severe scoliotic deformity of the thoracolumbar spine; and epiphyseo-metaphyseal enlargement of the femur.

**a**

- hypermethylated
- hypomethylated

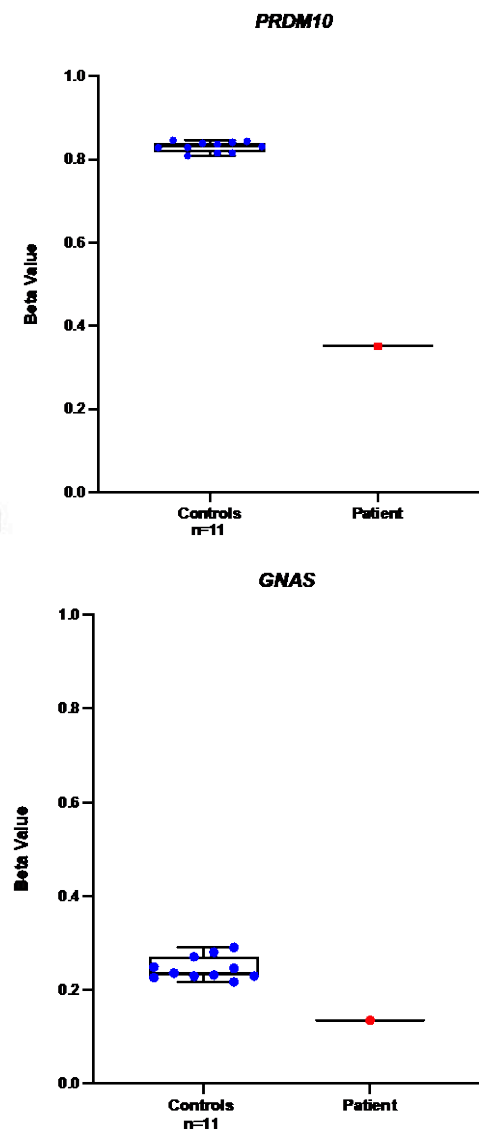
**b**

Table 1: Clinical features of the reported patients with Moreno-Nishimura-Schmidt overgrowth syndrome.

<b>Manifestations</b>	Moreno <i>et al.</i> , 1974	Nishimura <i>et al.</i> , 2004	Ab Sadeghi-Nejad <i>et al.</i> , 2005	Schmidt <i>et al.</i> , 2007	Handa <i>et al.</i> , 2017	Proband
<b>Gestational age</b>	Term	38 weeks	35 weeks	34 weeks	37 weeks	Term
Birth length and weight	60 cm/6,870 g	64.8 cm/ 6,100 g	61 cm/6,400 g	61 cm/6,600 g	54.5 cm/ 4,108 g	61 cm/5,600 g
Macrocephaly	+	+	+	+	+	+
Dysmorphic facial features	+	+	+	+	+	+
Prominent supraorbital ridges	+	+	+	+	+	+
Loose skin/hernia	ND/+	+/+	-/+	+/+	ND/+	+/+
Thoracic dysplasia	ND	+	+	+	+	+
Neonatal contractures of joints	+	ND	-	+	+	-
Lumbar kyphosis/platyspondyly	+/ND	+/+	+/ND	+/+	+/+	+/+
Widened metaphysis	+	+	+	+	+	+
Vertebral bodies abnormalities	+	+	+	+	+	+
Rhizomelia	ND/ND	+	-	+	-	-
Puberty	ND	Delayed	Normal	Precocious	Delayed	-
Hypothyroidism	ND	-	-	+	ND	-
Hypoglycemia/insulin hypersensitivity	ND/ND	ND/ND	-/-	+/+	ND/+	-/-
Low IGF-I/GH	ND/ND	+/-	-/-	+/+	+/ND	+/+
Decreased bone density	ND	ND	+	+	ND	+
Atrial septal defect	-	-	+	ND	ND	+
Difficulty to move	ND	+	+	+	ND	
Hoarse voice	+	+	+	+	+	+
Intellectual disability	ND	-	-	+	-	+
*Table is reproduced and updated from Schmidt H. <i>et al.</i> , 2007. ND: Not determined						





## **Supplementary Document 1:**

### ***Material and methods:***

#### *1. Study subjects*

The patient, a boy, is the 4<sup>th</sup> and youngest child of a Lebanese non consanguineous family. He underwent extensive work-up and routine blood tests.

#### *2. Whole Exome Sequencing (WES):*

Genomic DNA was isolated from peripheral blood by standard salt-precipitation methods (Miller et al., 1988). Exon capture and sequencing: The exome was captured using the SureSelect Human All Exons, reagents (Agilent Inc<sup>®</sup> Santa Clara, CA) according to the manufacturer's standard protocol. The concentration of each library was determined using Agilent's QPCR NGS Library Quantification Kit (G4880A). Samples were pooled prior to sequencing with a final concentration of each sample equal to 10nM. Sequencing was performed on the Illumina HiSeq2000 platform using TruSeq v3 chemistry.

Mapping and alignment: Reads files (FASTQ) were generated from the sequencing platform via the manufacturer's proprietary software. Reads were aligned to the hg19/b37 reference genome using the Burrows-Wheeler Aligner package v0.6.1 (Li et al., 2009). Local realignment of the mapped reads around potential insertion/deletion (Indel) sites was carried out with the Genome Analysis Tool Kit (GATK) (McKenna et al., 2010). Duplicate reads were marked using Picard v1.62. Additional BAM file manipulations were performed with SAM tools 0.1.18 (Li and Durbin, 2009). Base quality (Phred scale) scores were recalibrated using GATK's covariance recalibration. SNP and Indel variants were called for each sample using the GATK Unified Genotyper (DePristo et al., 2011). Variants were called using high stringency settings and annotated with VarAFT software 1.61 (Desvignes et al., 2018) containing information from dbSNP147 and ExAC (<http://exac.broadinstitute.org/>). Variants are filtered for only protein-altering variants, including truncating variants (stop gain/loss, start loss, or frameshift), canonical splice-site variants, inframe indels affecting protein-coding regions, variants within the intron–exon boundary (ten bases flanking the exonic boundaries), and missense variants based on frequency of occurrence in dbSNPv137 (<1%), ExAC/gnomAD v2.11 (<1%) and our in-house database (<1%) containing data from 300 exomes.

### Overgrowth syndromes genetic panel:

*AKT1, APC2, BGN, CDKN1C, DNMT3A, EFEMP1, EZH2, FBN1, FBN2, FGFR3, FGFR1, GPC5, GPR101, H19, IGF1R, IGF2, KCNQ1, KCNQ1OT1, NFIX, NPCC, NPR2, NPR3, NSD1, PIK3CA, PTCH1, SETD2, SHANK3, SMAD2, SMAD3, TGFB1, TGFB2, TGFB3, TGFB2, ZBTB20*

### 3. *Sanger sequencing:*

Genomic sequence of *IGF2* (NM\_178170) was obtained from UCSC Genomic Browser. Primers used for PCR amplification were designed using Primer3 software (<http://frodo.wi.mit.edu>) to amplify exon 2 of the gene harboring the *IGF2* variant detected by WES. PCR reactions were performed using Taq DNA polymerase (Invitrogen Life Technologies, Carlsbad, CA, USA). PCR fragments were run on 1% agarose gel. The fragments were purified using « SIGMA-ALDRICH <sup>TM</sup> » kit and then sequenced using the Big Dye\_Terminator v1.1 Cycle Sequencing Kit (Applied Biosystems, Foster City, CA, USA). Sequence reaction was purified on Sephadex G50 (Amersham Pharmacia Biotech, Foster City, CA), and then loaded into an ABI3500 system after the addition of Hidi formamide. Electropherograms were analyzed using Sequence Analysis Software version 5.2 (Applied Biosystems) and then aligned with the reference sequences using ChromasPro v1.7.6.1 (Technelysium, Queensland, Australia)

### 4. Array-based comparative genomic hybridization (*CGH*) analysis.

Genomic DNA was amplified and purified. Following denaturation of probe DNA, hybridization was carried out with the Affymetrix Cytogenetics Whole-Genome 2.7M Array following the manufacturers' standard protocol. Data was collected using GeneChip Scanner 3000 7G and CEL files were analyzed using Affymetrix Chromosome Analysis Suite software (ChAS v.1.0.1).

### 5. Epigenetic studies

Genome-wide DNA methylation profiling of peripheral blood DNA was performed via the Illumina Methylation EPIC arrays. Genomic DNA (~500 ng) was bisulfite converted via the EZ DNA Methylation Kit (Zymo Research, Irvine, CA, USA) according to the manufacturer's instructions. Following whole-genome amplification and enzymatic fragmentation, DNA was hybridized to the Infinium Methylation EPIC Bead Chips. Next, samples were washed and primers hybridized to the DNA were labeled and stained. BeadChips were scanned using an Illumina iScan and raw intensity data files files were exported to RnBeads in R (McEwen et al., 2018). Probes

overlapping SNPs ( $n = 17371$ ) and probes with unreliable measurements ( $n = 2085$ ) were filtered out. Data normalization was performed via Dasen, and subsequently 19020 probes overlapping sex chromosomes were excluded as well as 2983 probes overlapping specified context. In total, 825436 probes were retained for further analysis. A method for single sample case-control analysis, using the Crawford-Howell t-test to compare logit transformed M-values, was applied (Rezwan et al., 2015) and p-values were corrected for multiple testing using Bonferroni correction (Hernandez Mora et al., 2018). The methylglm function (methylGSA package) (Ren and Kuan, 2019) was then used to perform Gene Ontology (GO) enrichment for the 476 CpG sites following adjustment for the number of probes per gene on Infinium Methylation EPIC arrays.

### ***References related to methods:***

- DePristo, M.A., Banks, E., Poplin, R., Garimella, K.V., Maguire, J.R., Hartl, C., Philippakis, A.A., del Angel, G., Rivas, M.A., Hanna, M., McKenna, A., Fennell, T.J., Kernytsky, A.M., Sivachenko, A.Y., Cibulskis, K., Gabriel, S.B., Altshuler, D., Daly, M.J., 2011. A framework for variation discovery and genotyping using next-generation DNA sequencing data. *Nat. Genet.* 43, 491–498. <https://doi.org/10.1038/ng.806>
- Desvignes, J.-P., Bartoli, M., Delague, V., Krahn, M., Miltgen, M., Bérout, C., Salgado, D., 2018. VarAFT: a variant annotation and filtration system for human next generation sequencing data. *Nucleic Acids Res.* <https://doi.org/10.1093/nar/gky471>
- Hernandez Mora, J.R., Tayama, C., Sánchez-Delgado, M., Monteagudo-Sánchez, A., Hata, K., Ogata, T., Medrano, J., Poo-Llanillo, M.E., Simón, C., Moran, S., Esteller, M., Tenorio, J., Lapunzina, P., Kagami, M., Monk, D., Nakabayashi, K., 2018. Characterization of parent-of-origin methylation using the Illumina Infinium MethylationEPIC array platform. *Epigenomics* 10, 941–954. <https://doi.org/10.2217/epi-2017-0172>
- Li, B., Krishnan, V.G., Mort, M.E., Xin, F., Kamati, K.K., Cooper, D.N., Mooney, S.D., Radivojac, P., 2009. Automated inference of molecular mechanisms of disease from amino acid substitutions. *Bioinforma. Oxf. Engl.* 25, 2744–2750. <https://doi.org/10.1093/bioinformatics/btp528>
- Li, H., Durbin, R., 2009. Fast and accurate short read alignment with Burrows-Wheeler transform. *Bioinforma. Oxf. Engl.* 25, 1754–1760. <https://doi.org/10.1093/bioinformatics/btp324>
- McEwen, L.M., Jones, M.J., Lin, D.T.S., Edgar, R.D., Husquin, L.T., MacIsaac, J.L., Ramadori, K.E., Morin, A.M., Rider, C.F., Carlsten, C., Quintana-Murci, L., Horvath, S., Kobor, M.S., 2018. Systematic evaluation of DNA methylation age estimation with common preprocessing methods and the Infinium MethylationEPIC BeadChip array. *Clin. Epigenetics* 10, 123. <https://doi.org/10.1186/s13148-018-0556-2>

- McKenna, A., Hanna, M., Banks, E., Sivachenko, A., Cibulskis, K., Kernytsky, A., Garimella, K., Altshuler, D., Gabriel, S., Daly, M., DePristo, M.A., 2010. The Genome Analysis Toolkit: a MapReduce framework for analyzing next-generation DNA sequencing data. *Genome Res.* 20, 1297–1303. <https://doi.org/10.1101/gr.107524.110>
- Miller, S.A., Dykes, D.D., Polesky, H.F., 1988. A simple salting out procedure for extracting DNA from human nucleated cells. *Nucleic Acids Res.* 16, 1215.
- Ren, X., Kuan, P.F., 2019. methylGSA: a Bioconductor package and Shiny app for DNA methylation data length bias adjustment in gene set testing. *Bioinforma. Oxf. Engl.* 35, 1958–1959. <https://doi.org/10.1093/bioinformatics/bty892>
- Rezwan, F.I., Docherty, L.E., Poole, R.L., Lockett, G.A., Arshad, S.H., Holloway, J.W., Temple, I.K., Mackay, D.J., 2015. A statistical method for single sample analysis of HumanMethylation450 array data: genome-wide methylation analysis of patients with imprinting disorders. *Clin. Epigenetics* 7, 48. <https://doi.org/10.1186/s13148-015-0081-5>

**Supplementary Table 1: Gene ontology enrichment analysis for the differentially methylated CpG sites in the patient after adjusting for the number of CpG sites per gene on the Illumina Epic arrays.**

<b>ID</b>	<b>Description</b>	<b>Size</b>	<b>p-value</b>	<b>p-adjusted</b>
<b>GO:0008168</b>	<b>methyltransferase activity</b>	<b>399</b>	<b>2.00E-16</b>	<b>1.00E-13</b>
<b>GO:0016741</b>	<b>transferase activity, transferring one-carbon groups</b>	<b>417</b>	<b>2.00E-16</b>	<b>1.00E-13</b>
<b>GO:0005253</b>	<b>anion channel activity</b>	<b>139</b>	<b>7.00E-06</b>	<b>2.00E-03</b>
<b>GO:0005254</b>	<b>chloride channel activity</b>	<b>111</b>	<b>7.00E-06</b>	<b>2.00E-03</b>
<b>GO:0090630</b>	<b>activation of GTPase activity</b>	<b>105</b>	<b>7.00E-06</b>	<b>2.00E-03</b>
<b>GO:0016482</b>	<b>cytosolic transport</b>	<b>205</b>	<b>2.00E-04</b>	<b>4.00E-02</b>
<b>GO:0016874</b>	<b>ligase activity</b>	<b>297</b>	<b>3.00E-04</b>	<b>4.00E-02</b>
<b>GO:0046887</b>	<b>positive regulation of hormone secretion</b>	<b>142</b>	<b>3.00E-04</b>	<b>4.00E-02</b>
<b>GO:0090277</b>	<b>positive regulation of peptide hormone secretion</b>	<b>109</b>	<b>3.00E-04</b>	<b>4.00E-02</b>
<b>GO:1901654</b>	<b>response to ketone</b>	<b>197</b>	<b>3.00E-04</b>	<b>4.00E-02</b>
<b>GO:0005741</b>	<b>mitochondrial outer membrane</b>	<b>240</b>	<b>0.00038174</b>	<b>0.03864624</b>