



HAL
open science

Gene fusions in poroma, porocarcinoma and related adnexal skin tumours: An update

Thibault Kervarrec, Daniel Pissaloux, Franck Tirode, Arnaud de La Fouchardiere, Pierre Sohier, Eric Frouin, Aymeric Hamard, Roland Houben, David Schrama, Anne Barlier, et al.

► To cite this version:

Thibault Kervarrec, Daniel Pissaloux, Franck Tirode, Arnaud de La Fouchardiere, Pierre Sohier, et al.. Gene fusions in poroma, porocarcinoma and related adnexal skin tumours: An update. *Histopathology*, 2024, 84 (2), pp.266-278. 10.1111/his.15023 . hal-04254195

HAL Id: hal-04254195

<https://amu.hal.science/hal-04254195v1>

Submitted on 15 Jul 2024

HAL is a multi-disciplinary open access archive for the deposit and dissemination of scientific research documents, whether they are published or not. The documents may come from teaching and research institutions in France or abroad, or from public or private research centers.




L'archive ouverte pluridisciplinaire **HAL**, est destinée au dépôt et à la diffusion de documents scientifiques de niveau recherche, publiés ou non, émanant des établissements d'enseignement et de recherche français ou étrangers, des laboratoires publics ou privés.



Distributed under a Creative Commons Attribution - NonCommercial - NoDerivatives 4.0 International License

REVIEW

Gene fusions in poroma, porocarcinoma and related adnexal skin tumours: An update

Thibault Kervarrec,^{1,2,3}  Daniel Pissaloux,⁴  Franck Tirode,^{4,5}
Arnaud de la Fouchardière,^{1,4,5} Pierre Sohier,^{1,6,7} Eric Frouin,^{1,8}  Aymeric Hamard,²
Roland Houben,⁹ David Schrama,⁹ Anne Barlier,^{10,11} Bernard Cribier,^{1,12}
Maxime Battistella^{1,13} & Nicolas Macagno^{1,10,14}

¹CARADERM, French Network of Rare Cutaneous Cancer, Lille, ²Department of Pathology, University Hospital of Tours, ³'Biologie des infections à polyomavirus' Team, UMR1282 INRAE, University of Tours, Tours, ⁴Department of Biopathology, Center Léon Bérard, ⁵Centre Léon Bérard, Cancer Research Center of Lyon, Equipe Labellisée, University of Lyon, Université Claude Bernard Lyon 1, INSERM 1052, CNRS 5286, Lyon, ⁶Department of Pathology, Hôpital Cochin, AP-HP, AP-HP Centre – Université Paris Cité, ⁷Faculté de Médecine, Université Paris Cité, Paris, ⁸Department of Pathology, University Hospital of Poitiers, University of Poitiers, LITEC, Poitiers, France, ⁹Department of Dermatology, Venereology and Allergology, University Hospital Würzburg, Würzburg, Germany, ¹⁰Aix-Marseille Univ, INSERM, MMG, U1251, Marmara Institute, ¹¹Laboratory of Molecular Biology, La Conception Hospital, Marseille, ¹²Clinique Dermatologique, Hôpital Civil, Hôpitaux Universitaires, Université de Strasbourg, Strasbourg, ¹³Department of Pathology, Hospital Saint-Louis, AP-HP, Université Paris Cité, INSERM U976, Paris and ¹⁴Department of Pathology, APHM, Timone University Hospital, Marseille, France

de la Fouchardière T, Pissaloux D, Tirode F, Sohier A, Kervarrec P, Frouin E, Hamard A, Houben R, Schrama D, Barlier A, Cribier B, Battistella M & Macagno N
(2024) *Histopathology* 84, 266–278. <https://doi.org/10.1111/his.15023>

Gene fusions in poroma, porocarcinoma and related adnexal skin tumours: An update

Poroma is a benign sweat gland tumour showing morphological features recapitulating the superficial portion of the eccrine sweat coil. A subset of poromas may transform into porocarcinoma, its malignant counterpart. Poroma and porocarcinoma are characterised by recurrent gene fusions involving *YAP1*, a transcriptional co-activator, which is controlled by the Hippo signalling pathway. The fusion genes frequently involve *MAML2* and *NUTM1*, which are also

rearranged in other cutaneous and extracutaneous neoplasms. We aimed to review the clinical, morphological and molecular features of this category of adnexal neoplasms with a special focus upon emerging differential diagnoses, and discuss how their systematic molecular characterisation may contribute to a standardisation of diagnosis, more accurate classification and, ultimately, refinement of their prognosis and therapeutic modalities.

Keywords: *NUTM1*, NUT carcinoma, *PAK2*, porocarcinoma, poroma, *YAP1*

Introduction

Glandular adnexal tumours have been classified according to their differentiation and developmental

origin into the apocrine and eccrine groups, which are related to the folliculo–sebaceous–apocrine unit and the eccrine glands, respectively. In the 5th World Health Organisation (WHO) classification of cutaneous

Address for correspondence: T Kervarrec, Department of Pathology, Hôpital Trousseau, CHRU de Tours, 37044 Tours Cedex 09, France.
e-mail: thibaultkervarrec@yahoo.fr

© 2023 The Authors. *Histopathology* published by John Wiley & Sons Ltd.

This is an open access article under the terms of the [Creative Commons Attribution-NonCommercial-NoDerivs](https://creativecommons.org/licenses/by-nc-nd/4.0/) License, which permits use and distribution in any medium, provided the original work is properly cited, the use is non-commercial and no modifications or adaptations are made.

tumours, the term 'poroma' defines a group of benign sweat gland tumours with differentiation towards the intra-epidermal superficial portion of the sweat gland.^{1,2} Porocarcinoma is its malignant counterpart, with numerous reports supporting progression from poroma in a subset of cases.^{3–5}

Regarding the prognosis of porocarcinoma, data are conflicting between the early and most recent series.^{3,6–10} Low-grade porocarcinomas may raise a differential diagnosis with poromas, whereas high-grade tumours must be distinguished from other poorly differentiated carcinomas, especially squamous cell carcinoma.^{3,11} In this context, the lack of reliable diagnostic criteria and lack of detection of a specific molecular hallmark may be the cause of some of these data discrepancies. Furthermore, there is currently no consensus on a therapeutic strategy for patients with advanced disease.

In addition to potential mutations that activate oncogene products such as *EGFR* and *HRAS*, or inactivate tumour suppressors such as *TP53* and *RB1*,^{12,13} the frequent presence of mutually exclusive *YAP1::MAML2* and *YAP1::NUTM1* fusions has been shown to be a common driving oncogenic event in poroma and porocarcinoma.¹⁴ Furthermore, immunohistochemical evaluation of *YAP1* (C-terminus part) and *NUT* has been shown to be a specific diagnostic surrogate for molecular testing.^{11,15–18} Interestingly, the systematic examination of large cohorts of cutaneous skin tumours for the expression of *YAP1*, *NUT* and their related fusion transcripts has allowed the identification of novel and emerging tumour entities related to *NUTM1* fusion.^{11,19–21}

In this review, we aim to discuss the clinical, morphological and molecular features of poroma, porocarcinoma and related cutaneous tumour entities, with a focus upon emerging differential diagnoses. The contribution of genetic characterisation of these tumours to a more accurate classification will also be discussed.

Poroma and porocarcinoma: general features

There are many different terms used to describe poroma and they all represent a different expression of the same tumour. 'Classic poroma', 'hidroacanthoma simplex' (intra-epidermal poroma), 'dermal duct tumour' and 'poroid hidradenoma' are possible terms used by the pathologist according to their location (epidermal or dermal) in the skin, hence this historical terminology (Figure 1).

The use of the term 'eccrine poroma' spread considerably after its first description in 1956 by Pinkus *et al.*,²² who reported 'five tumors thought to be related to the eccrine sweat pore in as much as they have histologic features of the intraepidermal part of the sweat duct'. The other terms were introduced later by Smith and Coburn, Winkelman and McLeod and Abenoza and Ackerman, respectively.^{22–25} In parallel, poroid tumours with apocrine, sebaceous and follicular differentiation have also been reported, and some authors have considered them as variants of poroma with aberrant differentiation while others have suggested that they belong to a distinct group of adnexal tumours referred to as 'apocrine' or 'holocrine poroma'.^{1,2,26}

Most cases present as solitary tumours in adults. Clinically, the different histological subtypes correlate with different clinical presentations due to their architectural patterns: erythematous patch, well-defined flat or keratotic plaque, papule and nodule. Although some cases may have the colour of normal skin, poromas range from fleshy red to dark brown due to their dense angiomatous vascularisation, similar to pyogenic granuloma or other benign vascular tumours. The classic poroma involves the soles in more than half of the reported cases.^{27,28} Intra-epidermal poroma (hidroacanthoma simplex) often occurs on the extremities, especially on the legs in adults.²⁹ The sudden appearance of multiple poromas is a rare phenomenon referred to as poromatosis.^{30,31} Multiple tumours have been described after chemotherapy and immunosuppression, especially after allogeneic haematopoietic stem cell transplantation.³²

As the overall architectural pattern varies between the four poroma subtypes, the diagnosis of a poroid tumour relies upon the identification of its specific cytology, which consists of a mixture of poroid and cuticular cells often associated with duct formation and necrosis *en masse*^{21,22} (Figure 1). Poroid cells are often the predominant type of cells, with bland, monotonous cytology with round to oval nuclei and scarce basophilic cytoplasm. Cuticular cells are less common, sometimes absent, and characterised by more abundant eosinophilic cytoplasm and frequent association with duct formation. In some cases, ductal differentiation is only visible at high magnification in the form of a vacuole around which a few cells are organised, while in other cases it is very easy to identify morphologically. The ductal differentiation can be highlighted by CEA or EMA immunohistochemistry with variable sensitivity.^{3,22,26} Mild pleomorphism can be observed in cuticular cells correlating with positivity in p53 immunohistochemical staining, but

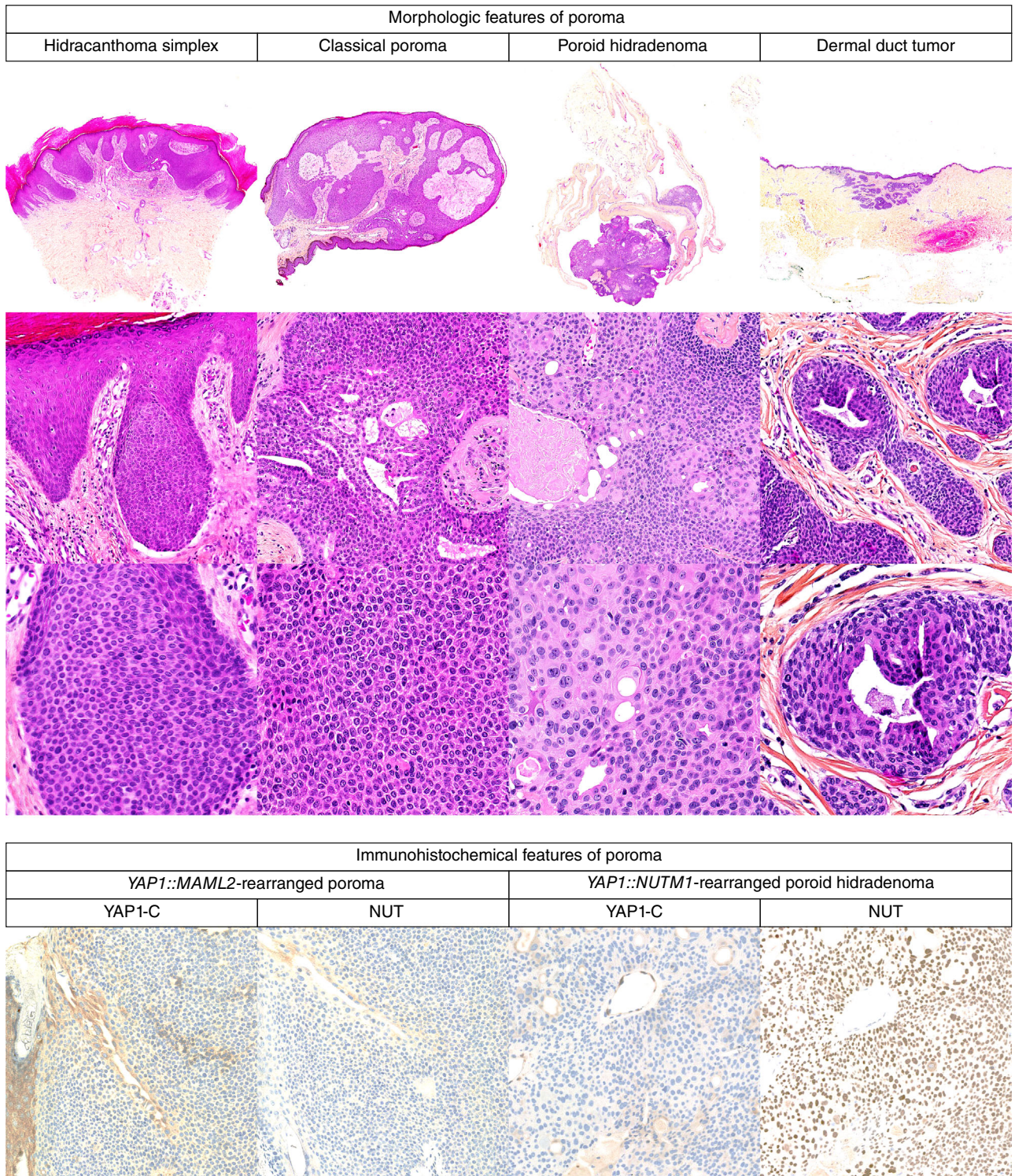


Figure 1. Morphological and immunohistochemical features of poroma histotypes. A hidroacanthoma simplex, a classical poroma, a poroid hidradenoma and a dermal duct tumour are depicted. All specimens are composed of a mixture of poroid and cuticular cells. Hidroacanthoma simplex consists in a strictly intra-epidermal tumour proliferation while classical poroma is connected to the epidermis and located in the dermis. Poroid hidradenoma and dermal duct tumours have deep dermal location without epidermal connection in most cases. All *YAP1*-rearranged specimens show loss of expression of the C-terminal part of *YAP1* by immunohistochemistry, while *NUT* is only expressed in cases with *YAP1::NUTM1* fusions.

not predicting aggressive behaviour.²⁷ All poroma subtypes show this specific cytology.

The more common pattern, classic poroma, shows an exo-endophytic nodular silhouette with multiple connections to the epidermis and frequent vertical extensions into the dermis. The intra-epidermal pattern of poroma, hidroacanthoma simplex, consists of intra-epidermal round nests and aggregates that may be confused with clonal seborrheic keratosis.^{25,28,33} The dermal pattern, poroid hidradenoma, is characterised by the formation of one or more large dermal nodules deep in the dermis, often with cystic changes. The architecture of poroid hidradenoma is similar to that of nodular hidradenoma, hence the name, but differs in its dual poroid/cuticular cytology and the absence of pale or mucosecreting cells.³⁴ Finally, the rarest pattern is the dermal duct tumour, which presents with multiple solid and/or cystic aggregates located in the reticular dermis.^{23,35} Several variations of these subtypes have been described, including pigmented and clear cell variants.^{36,37}

Porocarcinoma is the malignant counterpart of poroma.³ Invasive porocarcinoma may develop *de novo* or in association with *in-situ* porocarcinoma or benign poroma in approximately 20% of cases.³

There are discrepancies regarding the prognosis of porocarcinoma, with reports of a 10-year overall survival estimated at 55%,⁹ while others have reported an excellent outcome at a localised stage.^{3,6,7,10} The rate of regional lymph node metastasis ranges from 19 to 57%, depending on the study.^{3,38} It is possible that at least a part of these variations are related to biases arising from referral patterns and selective reporting (aggressive cases are more likely to be referred to academic institutions for diagnostic confirmation and management). Moreover, these conflicting results are likely to reflect the incidence of porocarcinoma in the context of lack of commonly accepted diagnostic criteria as well as deficiencies in applying molecular characterisation.³⁹

Porocarcinoma may be *in situ* (intra-epidermal) or invasive. Twenty per cent of cases present as the emergence of a malignant clone associated with a benign poroma. Porocarcinoma has features reminiscent of poroma, such as poroid cytology and duct formation, but with worrisome features such as severe nuclear atypia (pleomorphism), high mitotic index, infiltrative borders, perineural invasion and lymphovascular invasion.³ Necrosis *en masse* can be seen in both benign poroma and porocarcinoma, and is not a criterion of malignancy in this setting.

Morphological and immunohistochemical evidence of duct formation is a clue to distinguish

porocarcinoma⁴⁰ from other poorly differentiated skin cancers, particularly non-keratinising squamous cell carcinoma, which is the main differential diagnosis in current practice.^{3,11} However, single-cell necrosis can be morphologically mistaken for duct formation and poorly differentiated porocarcinoma may lack obvious ductal differentiation. In this context, identification of a precursor poroma (when present) is a diagnostic clue to avoid misinterpretation.

Fusions of YAP1 are frequent in poroma and porocarcinoma

The oncogenic determinants of poroma and porocarcinoma development have long remained unknown. Although HPV-induced oncogenesis has been historically suspected in the past, there is currently no scientific evidence to support this hypothesis.¹ In 2016 and 2018, studies of non-synonymous DNA mutations in two small series of poromas and porocarcinomas revealed hot-spot *HRAS* mutations in a minority of cases.^{13,41} These observations were consistent with the view that poromas may arise from *Naevus sebaceus*, a cutaneous hamartoma genetically characterised by *HRAS* mutations.^{42–46} Furthermore, frequent *TP53* mutations have also been described in poroma⁴² and porocarcinoma.^{12–14}

In addition to these and some further oncogenic mutations, which are commonly found in many different tumour entities, highly specific genetic alterations were discovered in 2019 by Sekine *et al.*, who demonstrated the presence of *YAP1::MAML2*, *YAP1::NUTM1* and *WWTR1::NUTM1* fusion genes in 85% ($n = 92$ of 104) and 64% ($n = seven$ of 11) of poroma and porocarcinoma cases, respectively (Figure 2). These recurrent fusions were later confirmed by others,^{16–18,39,7} even in the setting of poromatosis,^{14,48} in which identification of *YAP1::MAML2* fusions with distinct breakpoints in the same patient suggests that multiples and independent double-strand DNA breaks, probably induced by the chemotherapy, result in multiple poroma formations.

YAP1 (yes-associated protein 1) and TAZ (transcriptional co-activator with PDZ-binding motif encoded by the *WWTR1* gene) serve as transcriptional co-activators repressed by the Hippo pathway and function as crucial regulators of tissue homeostasis.^{49,50}

The Hippo signalling pathway is well conserved during evolution and is necessary to regulate organogenesis, tissue homeostasis and tissue repair.^{49,50} In the nucleus, YAP1 and TAZ proteins form a complex

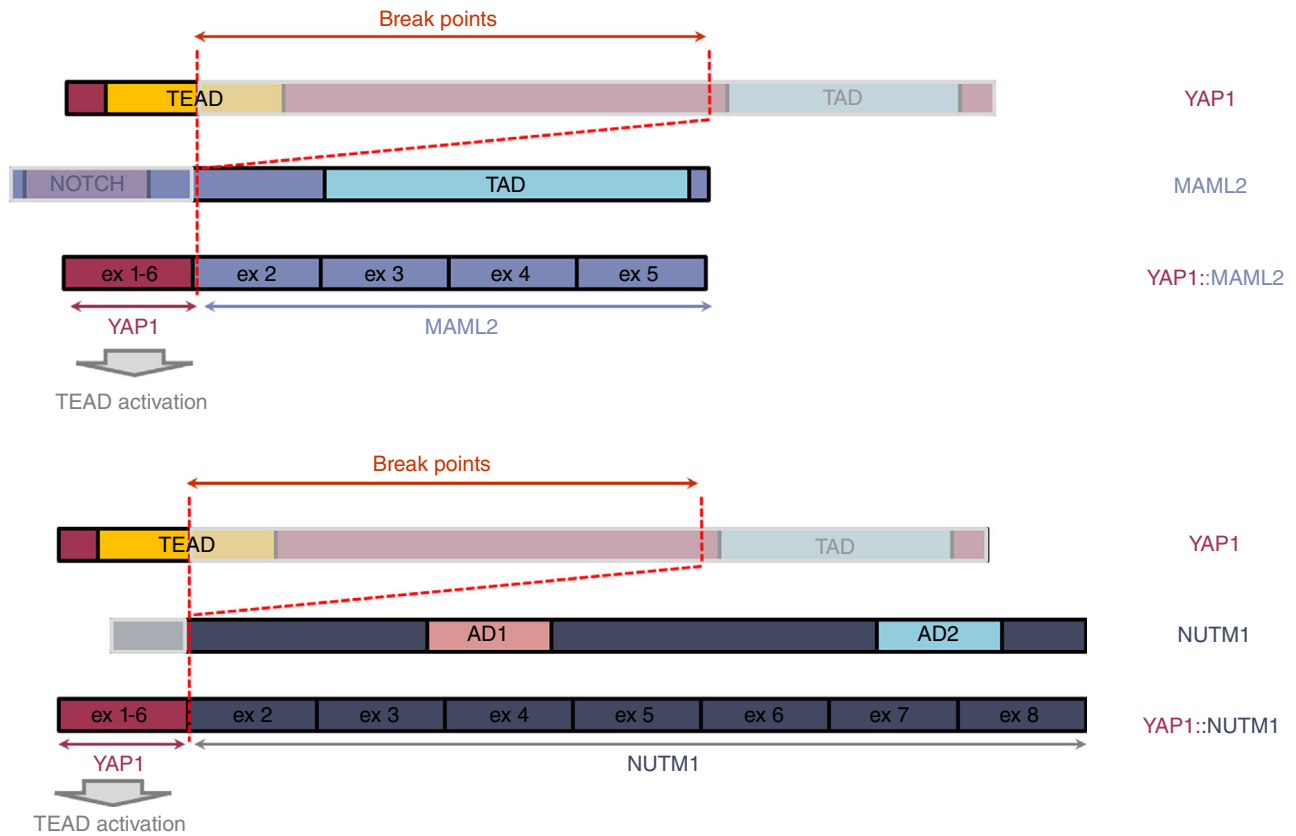


Figure 2. Schematic representations of the *YAP1::MAML2* and *YAP1::NUTM1* fusion transcripts observed in eccrine poromas and porocarcinomas. *YAP1::MAML2* fusion transcripts include the N-terminal portion [exon 1 to exons 1–6 of *YAP1* fused to exons 2–5 of *MAML2* (*YAP1* breakpoints: chr 11:101,981,900(+)-chr11:102 094 352(+); *MAML2* breakpoint: chr11:95 826 681(-)). *YAP1::NUTM1* fusion transcripts are composed of N-terminal portion (exon 1 to exons 1–4) of *YAP1* fused to exons 2–8 of *NUTM1* [*YAP1* breakpoints: chr 11:101 981 900(+)-chr11:102 056 861(+); *NUTM1* breakpoint: chr15:34 640 169(+)]. *YAP1* contains several functional domains as follows: TEAD (transcriptional enhanced associate domain)¹⁴ and TAD (transcriptional activation domain), which is necessary for proteasomal degradation.⁵² *MAML2* contains several domains as follows: Notch interacting domain which signalling pathway is known to promote cell proliferation¹⁰¹ and TAD. *NUT* contains two acidic transcriptional activation domains (AD1 and AD2).⁷⁷ All fusions showed preservation of TEAD domains leading to TEAD activation.

with the transcription factor TEAD (transcriptional enhanced associate domain) resulting in the activation of key target genes, leading ultimately to cell proliferation, self-renewal, differentiation and survival of the cells. Under physiological conditions, activation of the Hippo pathway negatively regulates the activation of YAP and TAZ through the phosphorylation of these two proteins, resulting in their cytoplasmic retention and degradation.⁵¹

Experiments have suggested a potential oncogenic role of YAP with induction of epithelial–mesenchymal transition, reduction of apoptosis and promotion of proliferation. Dysregulation of the Hippo pathway has been observed in several malignancies, with YAP1 being described to act as either an oncogene or a tumour suppressor depending on the cellular context: hepatocellular carcinoma, non-small cell lung carcinoma,

breast carcinoma, oesophageal squamous cell carcinoma, ovarian and gastric cancers.^{52,53}

Although not common in most cancers, fusions of YAP1 have been reported in rare tumours such as supratentorial ependymoma,⁵⁴ meningioma,⁵⁵ a subset of epithelioid haemangi endothelioma with *TFE3* gene fusion⁵⁶ and a subset of low-grade fibromyxoid and sclerosing epithelioid sarcoma with *KMT2A*.⁵⁷ Similar to poroma and porocarcinoma, retiform and composite haemangi endothelioma have been reported to harbour *YAP1::MAML2* fusion.⁵⁸

Importantly, several of these *YAP1* fusions have been shown to be oncogenic in mice, and disruption of the TEAD-binding domain of *YAP1* fusions is sufficient to inhibit tumour formation.⁵⁹ In contrast to the *YAP1* 5'-portion of the fusion protein, the 3' partner was found to sometimes have partially lost its

enzymatic activity, but appears to be essential to provide a nuclear localisation signal. Hence, while at steady state conditions YAP1 is continuously shuttled between nucleus and cytoplasm, the fusion partner leads to constitutive nuclear localisation of the YAP1-fusion proteins and renders them resistant to negative Hippo pathway regulation by the Hippo pathway.⁵⁹

An interesting aspect of the *YAP1::MAML2* fusion protein found in poroma and porocarcinoma is that both individual proteins, namely YAP1 and MAML2, also interact in normal cells. Indeed, MAML1/2 have been shown to be essential for YAP/TAZ nuclear localisation and transcriptional activities.⁶⁰

As observed in other neoplasms associated with YAP1 fusions,⁵⁶ the *YAP1::MAML2* and *YAP1::NUTM1* fusions in poroma and porocarcinoma always include the N-terminal portion of YAP1 (exon 1) containing the TEAD binding domain. In parallel, the regulatory domains located in the C-terminal portion and containing part of the phosphorylation sites are variably lost.^{14,56}

As discussed below, this enables reliable screening by immunohistochemistry with an antibody directed against the C-terminal portion of YAP1, as its expression is absent in neoplastic cells with YAP1 fusion.^{11,15} While both cytoplasmic and nuclear signals were observed with the wild-type protein, the ectopic expression of the fusion proteins in HEK 293T resulted in an exclusive nuclear localisation.¹⁴ Accordingly, overexpression of the fusion proteins in fibroblast and keratinocyte cell lines resulted in activation of the TEAD reporter and enhanced anchorage-independent growth.¹⁴ These results confirmed that *YAP1::MAML2* and *YAP1::NUTM1* fusions induced the activation of TEAD and expression of its target genes, as previously shown in other cellular models,⁶¹ suggesting that TEAD activation may contribute, at least in part, to the oncogenesis of poroma and porocarcinoma. Interestingly, a recent CRISPR-Cas9 screen identified *YAP1::MAML2* fusions that drive Hippo pathway signalling as a specific vulnerability in cancer cells harbouring these alterations.⁶²

In parallel, the C-terminal NUT and MAML2 portions of the fusion proteins may also exert oncogenic activities in addition to providing a nuclear anchor for YAP1. This is suggested by the detection of an alternative *EMC7::NUTM1* fusion transcript in a case of poroma lacking YAP1 fusion.⁴⁷ This hypothesis is also supported by the description of recurrent gene fusions involving MAML2 and NUTM1 genes with other 5' partners in several other neoplasms.^{63–65}

MAML2 (mastermind-like transcriptional co-activator 2) is a co-activator of the Notch signalling

pathway, which is physiologically involved in tissue development and homeostasis.⁶⁶ In cutaneous tumours, fusion of MAML2 with either *CRTC1/3* or YAP1 has been observed in other sweat gland tumours; namely, hidradenoma and hidradenocarcinoma with *CRTC1/3::MAML2* fusion,^{63,64} but also in mesenchymal tumours such as composite and retransformant haemangioma with *YAP1::MAML2* fusion^{58,67} and in a subset of myxoinflammatory fibroblastic sarcoma.⁶⁸ In other organs, *CRTC1/3::MAML2* have been reported primarily in mucoepidermoid carcinoma,⁶⁹ which is thought to be the extracutaneous molecular analogue of hidradenoma/hidradenocarcinoma, while *YAP1::MAML2* or *KMT2A::MAML2* fusions were also in thymoma,⁷⁰ central nervous system tumours⁷¹ and haematological malignancies.⁷² Notably, in mucoepidermoid carcinoma with *CRTC1::MAML2* fusion, the oncogenic properties of the fusion protein were associated with alterations in two pathways in which the fusion partners are involved, as both constitutive activation of CREB⁷³ and disruption of the Notch pathways⁷⁴ were observed. Therefore, in addition to constitutive TEAD activation, it is possible that the activation of CREB and disruption of the Notch pathways by MAML2 contribute to the oncogenic properties of the protein in *YAP1::MAML2*-rearranged poroma and porocarcinoma.

The expression of NUT is normally restricted to the testis, and its involvement in male germ-cell maturation is well known.⁷⁵ By interacting with p300 and CBP, NUT increases the acetylation levels of the lysine residues K5 and K8 of histone 4.⁷⁵ In 2003, French and co-workers demonstrated recurrent *BRD4::NUTM1* fusion in an aggressive poorly differentiated extracutaneous neoplasm, namely NUT-carcinoma, affecting young adults. Such NUT-carcinoma cases are characterised by a t(15;19) translocation.^{65,76} In addition, *BRD3::NUTM1*, *NSD3::NUTM1* and *ZNF532/592::NUTM1* fusions have been detected in this tumour group,^{77,78} while other *NUTM1* rearrangements, including *CIC::NUTM1*⁷⁹ and *MGA::NUTM1*,⁸⁰ have been reported in mesenchymal neoplasms. In the NUT carcinoma model, *BRD4::NUTM1* fusion-protein expression is required to block cell differentiation and to maintain tumour cell proliferation,⁷⁷ and these activities have been shown to be mediated by complex interactions between BRD4 and NUT domains. According to French and co-workers, the fusion not only mediates NUT expression outside the testis, but 'both BRD4 and NUT in the fusion protein have distinct and cooperative roles in the oncogenic process',⁸¹

resulting in the epigenetic reprogramming of the target cell.^{82,83} In particular, the nuclear translocation of NUT due to the *BRD4::NUTM1* fusion is thought to contribute to the oncogenic properties of the fusion protein,^{65,81} therefore it is possible that in *YAP1::NUTM1* rearranged-tumours, translocation of the NUT protein into the nucleus¹⁴ contributes to the oncogenic process.

Therefore, although TEAD activation is likely to be an important contributor to the oncogenic process, further mechanistic investigations are required to characterise the full functional spectrum of each type of fusion protein and to identify the reasons for the specific association of these fusions with poroma and porocarcinoma.

Association between *YAP1* fusion type, histology and prognosis

Different clinical and histological features are associated with the different *YAP1* fusion partners in poroma and porocarcinoma. In fact, in the report by Sekine *et al.*,¹⁴ *YAP1::MAML2* was the most frequent alteration in hidroacanthoma simplex ($n =$ four of five) and classical poroma cases (64 of 91), whereas *YAP1::NUTM1* was highly prevalent in poroid hidradenoma ($n =$ four of six), dermal duct tumours (two of two) and head and neck poroma (15 of 27). The high prevalence of *YAP1::NUTM1* fusion in poroid hidradenoma has been confirmed by our group,⁴⁷ while due to their very low incidence,³⁵ no confirmatory study has yet demonstrated the prevalence of *YAP1::MAML2* and *YAP1::NUTM1* fusions in hidroacanthoma simplex and dermal duct tumours.

Apocrine poroma is another morphological subtype of adnexal tumour closely resembling eccrine poroma that was not included in the initial report by Sekine *et al.* In the current WHO classification of skin tumours, such tumours are currently considered as a variant of poroma.²⁹ As described above, apocrine poroma is characterised by a poroid cytology but also presents apocrine, sebaceous and/or follicular differentiation at least focally (Figure 3). Importantly, when our group determined the immunohistochemical and molecular profiles of 13 cases of apocrine poroma with follicular and sebaceous differentiation, *YAP1::MAML2* and *YAP1::NUTM1* fusion genes could not be identified; rather, whole transcriptome analysis⁸⁴ revealed recurrent rearrangements of the *PAK2* gene with different partners in all 13 cases of apocrine poroma with folliculo-sebaceous differentiation ($n =$ 13 of 13)⁸⁵ (Figure 2). Interestingly, a similar fusion of *PAK2* has already been identified once in

a metastatic porocarcinoma.⁸⁶ In the resulting fusion proteins, the *PAK2* kinase domain was conserved⁸⁷ while the regulatory N-terminal portion modulating *PAK2* activation was lost, suggesting a constitutive *PAK2* activation in apocrine poromas with folliculo-sebaceous differentiation. Notably, *PAK2* kinase has recently been identified as a *YAP1* activator.⁸⁸ Thus, different molecular alterations in eccrine and apocrine poroma may affect the same signalling pathway, ultimately leading to TEAD activation. Regardless of this hypothesis, it is likely that *PAK2* rearrangement is a critical oncogenic driver of apocrine poroma with folliculo-sebaceous differentiation, a close but distinct entity to eccrine poroma.⁸⁹

As tumours driven by *YAP1::MAML2*, *YAP1::NUTM1* and *PAK2* fusions are associated with close but distinct morphologies, these tumours may also be associated with various risks of transformation.¹⁴ Indeed, due to the frequent association of porocarcinoma with a benign poroma component, it is widely accepted that a progression from poroma to porocarcinoma can occur.³ This notion is now further supported by the presence of the same type of fusion genes in both poroma and porocarcinoma, suggesting it as a driving event. Interestingly, in the original publication by Sekine *et al.*, a higher prevalence of *YAP1::NUTM1* fusion in porocarcinoma (six of 11) than in poroma (21 of 104) initially suggested that the transition to carcinoma was more likely to occur in *NUTM1*-rearranged tumours. However, this result was not confirmed in other series.^{16,47}

Therefore, further studies are needed to determine whether the subtype of fusion is a factor that promotes malignant transformation, but also increases the risk of metastasis and affects survival. However, even if this is the case, the accumulation of additional genetic events is required for the transformation of poroma, Boscic *et al.* reported higher mutation frequencies between poroma and porocarcinoma using targeted sequencing.¹³ While *RAS* mutations were present in both entities in their study, they found mutations in the tumour suppressor genes *TP53*, *RB1*, *CDKN2A* and *PTEN* only in porocarcinoma cases. If confirmed by other studies, these mutations may represent molecular events contributing to the malignant transformation of poroid neoplasms.

In contrast, Sekine *et al.* concluded from their study that analysis of mutations in key cancer-related genes could not be used to discriminate between poroma and porocarcinoma.¹⁴ In fact, only three genes (*KRAS*, *SETD2* and *TP53*) were recurrently mutated in porocarcinoma (each in only two of the nine samples), but *RAS* mutations were detected only in

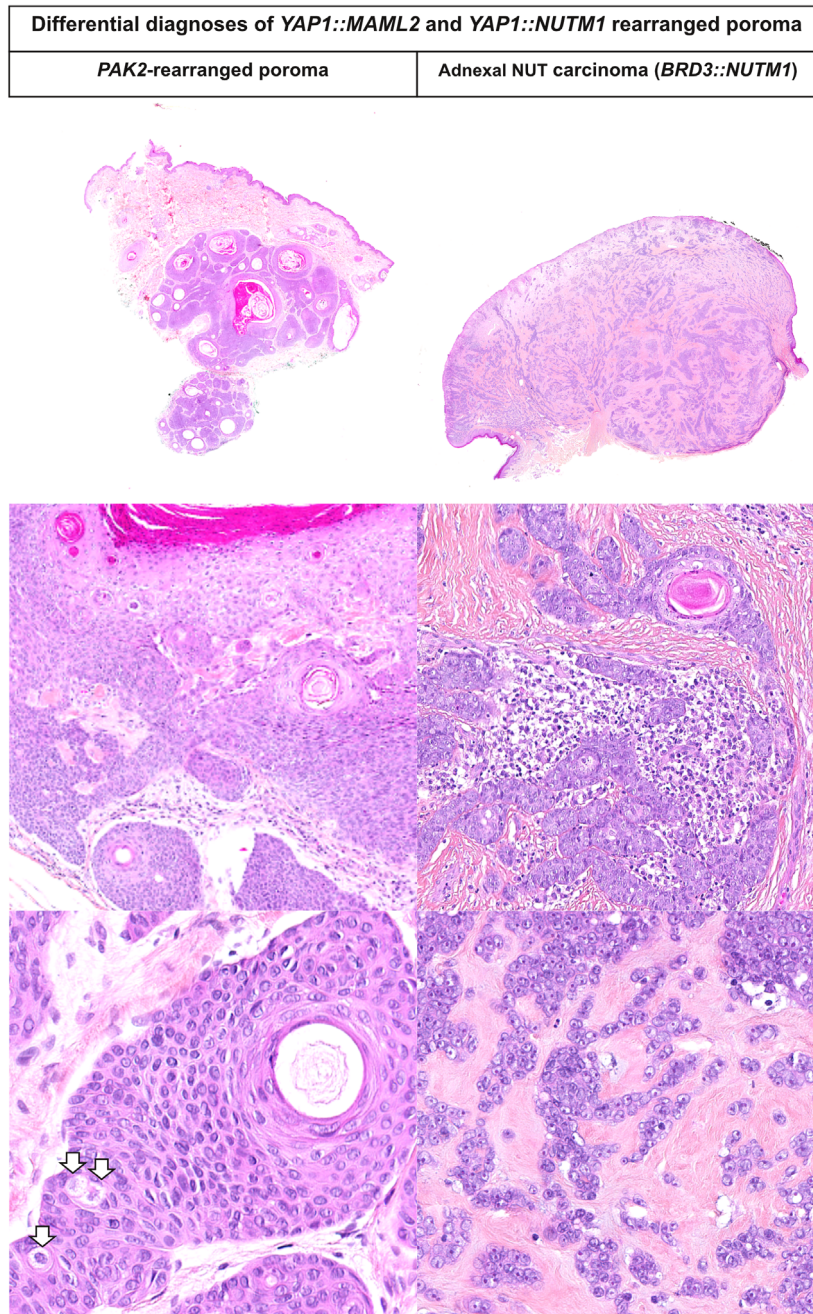


Figure 3. Microscopic features of poroma variants and mimickers. A *PAK2*-rearranged poroma with folliculo–sebaceous differentiation and a NUT adnexal carcinoma are depicted. The *PAK2*-rearranged poroma case is a dermal and subcutaneous tumour composed of poroid cells forming ducts and infundibulocystic structures. Sparse sebocytes (white arrows) are present in the tumour. An *EPHB3::PAK2* fusion was evidenced in this case. NUT adnexal carcinoma is a large and ulcerated tumour organised as islets and strands entrapped in a hyalinised stroma. Tumour cells have monotonous cytology with scant cytoplasm, clear chromatin and prominent nucleoli. A *BRD3::NUTM1* fusion transcript was evidenced in this case.

porocarcinoma cases without gene fusions, whereas *SETD2* and *TP53* mutations were also detected in poromas.¹⁴ Therefore, additional studies examining both fusion and mutational profiles in the same

cohort are certainly needed to conclusively address the question of malignant transformation of this group of adnexal tumours. Nevertheless, current data suggest that *RAS* mutations may characterise a

subset of poroma/porocarcinoma lacking *YAP1* fusion and further suggest that secondary genetic events, including inactivating mutations of tumour suppressor genes, contribute to poroma progression. In addition, epigenetic events may be involved.⁹⁰

As with other types of cancers, particularly sarcomas, which are also often driven by gene fusion, other molecular approaches such as whole-exome sequencing, the degree of genomic complexity, the application of transcriptomic molecular signatures and methylation profiles are promising approaches to refine the prognosis of these rare tumours.^{91–94}

Immunohistochemical detection of *YAP1* and *NUT* in the diagnosis of poroma and porocarcinoma: diagnostic performance and pitfalls

As previously established for other *YAP1*- or *NUT*-rearranged tumours,^{56 95} immunohistochemical tools could contribute to the identification of *YAP1::MAML2* and *YAP1::NUTM1*-rearranged poroma/porocarcinoma cases.

Indeed, as described above, *YAP1*-fusion proteins lack the C-terminal portion of *YAP1*. Therefore, immunohistochemistry with antibodies specific for the C-terminal part of the *YAP1* protein could serve as a surrogate marker for the presence of *YAP1* fusion, as previously demonstrated for *YAP1*-fused haemangiopericytoma.⁵⁶ Accordingly, Sekine *et al.* demonstrated nuclear positivity with a *YAP1* N-terminal-specific antibody in poroma and porocarcinoma, while a C-terminal-specific antibody revealed loss of *YAP1* in 96% of poroma ($n = 100$ of 104) and 64% of porocarcinoma ($n = 7$ of 11).¹⁴ In controls ($n = 84$), *YAP1* expression was always preserved with this antibody. In another study, Russell-Goldman *et al.*¹⁵ confirmed these findings by demonstrating loss of C-terminal *YAP1* expression in 80% of poroma ($n = 8$ of 10), 58% of porocarcinoma ($n = 7$ of 12) and in none of the controls ($n = 16$).

However, there are two limitations to immunohistochemistry using *YAP1* C-terminal-specific antibodies as a surrogate marker for gene fusions. First, it is not clear how the rearrangement of a single *YAP1* allele in tumour cells could lead to a complete loss of expression.⁵⁶

Secondly, loss of *YAP1* expression without fusion has been demonstrated in several tumour entities, such as *RB1*-deficient tumours.⁵³ This could be due to promoter methylation and/or related to *RB1* inactivation and E2F release.^{53,96,97} In this regard, by analysing a

large series of 543 cutaneous epithelial tumours, including 27 poromas and porocarcinomas, we recently demonstrated that while *YAP1* fusions were almost restricted to poroma and porocarcinomas, loss of *YAP1* C-terminal expression was additionally observed in most Merkel cell carcinomas ($n = 162$, 98%) and a subset of squamous cell carcinomas ($n = 14$, 15%), with both groups showing *RB1*-inactivation.¹¹ Consistent with the literature, we found that poorly differentiated squamous cell carcinoma, often arising from Bowen disease and lacking keratinisation, showed morphological overlap with porocarcinoma by reviewing cases initially diagnosed as porocarcinoma and referred to our expert centre for a second opinion. Importantly, while *YAP1::MAML2* and *YAP1::NUTM1* fusions were not detected in this setting, these tumours frequently harboured *RB1* mutations and combined loss of *RB1* and *YAP1* C-terminal expression on immunohistochemistry. Therefore, *YAP1* C-terminal immunohistochemistry alone did not discriminate between porocarcinoma and *RB1*-deficient poorly differentiated squamous cell carcinoma,⁹⁸ and should not be used as a surrogate marker in this context. A combination of *YAP1* C-terminal immunohistochemistry either with *YAP1* N-terminal or *RB1* detection is required.

As *NUT* protein expression is physiologically restricted to the testis, the detection of *NUT* in other organs, including the skin, is a sensitive and specific tool to identify *NUTM1*-rearranged tumours.⁹⁵ Accordingly, Sekine *et al.*¹⁴ detected nuclear expression of *NUT* in 24% of poroma cases ($n = 25$ of 100) and 54% of porocarcinoma cases ($n = 6$ of 11), whereas *NUT* was never expressed in other cutaneous tumours ($n = 87$). Interestingly, the evaluation of *NUT* expression in skin tumours in several independent studies^{15–17,47} confirmed the high specificity of *NUT* expression for the diagnosis of poroma and porocarcinoma, but also allowed identification of a new tumour entity, i.e. *NUT* adnexal carcinoma,^{19–21,99} an extremely rare tumour that will be mentioned as a provisional tumour entity in the 5th WHO classification of cutaneous tumours.

NUT adnexal carcinomas are cutaneous primary tumours analogous to *NUT* carcinomas of other organs. So far, only four cases with either *BRD3::NUTM1* or *NSD3::NUTM1* fusions have been published.^{19,20,99} One case with *BRD3::NUTM2B* may belong to the same spectrum.²¹ So far no primary cutaneous tumour with *BRD4::NUTM1* fusion has been identified. Although the small number of cases does not allow a definitive conclusion, the patients with cutaneous adnexal *NUT* carcinoma showed a better outcome

than patients with thoracic NUT carcinoma as observed in other organs.¹⁰⁰ NUT adnexal carcinoma appears as a poorly differentiated tumour that may show connection to the epidermis (Figure 3). The tumour consists of strands and cords of monotonous tumour cells with clear chromatin and prominent nucleoli. Formations of ducts and foci of keratinisation are combined in the tumour. Immunohistochemistry revealed expression of NUT in *NUTM1*-rearranged cases.^{19,20} Although additional cases are needed to fully characterise this new tumour entity, adnexal NUT carcinoma, together with the metastasis of extracutaneous NUT carcinoma, appears as a new differential diagnosis of porocarcinoma, especially in the case of NUT immunohistochemical positivity. In this setting, recognition of a distinctive architecture with formation of thin strands and isolated tumour cells, a characteristic cytology with fine/clear chromatin and prominent nucleoli, as well as detection of abrupt keratinisation foci, would allow NUT adnexal carcinoma to be distinguished from NUT-rearranged porocarcinoma.^{19–21,99}

Conclusion

In conclusion, the identification of recurrent gene fusions in poroma and porocarcinoma, namely *YAP1::MAML2* and *YAP1::NUTM1*, represents a major advance in our understanding of this subset of cutaneous adnexal tumours.

Following this molecular discovery, further studies of large genetically characterised series of poroma and porocarcinoma allowed the identification of new histological subtypes and mimickers and provided insight into the genetic determinants of transformation. Furthermore, studies based on an integrated histomolecular diagnosis of adnexal carcinomas are needed to establish their prognosis and to tailor the treatment modalities accordingly.

Acknowledgements

None to declare.

Conflicts of interest

The authors declare no conflicts of interest.

Data availability statement

Data sharing not applicable to this article as no datasets were generated or analysed during the current study.

References

- Harvell JD, Kerschmann RL, LeBoit PE. Eccrine or apocrine poroma? Six poromas with divergent adnexal differentiation. *Am. J. Dermatopathol.* 1996; **18**: 1–9.
- Kazakov DV, Kutzner H, Spagnolo DV *et al.* Sebaceous differentiation in poroid neoplasms: report of 11 cases, including a case of metaplastic carcinoma associated with apocrine poroma (sarcomatoid apocrine porocarcinoma). *Am. J. Dermatopathol.* 2008; **30**: 21–26.
- Robson A, Greene J, Ansari N *et al.* Eccrine porocarcinoma (malignant eccrine poroma): a clinicopathologic study of 69 cases. *Am. J. Surg. Pathol.* 2001; **25**: 710–720.
- Mishima Y, Morioka S. Oncogenic differentiation of the intraepidermal eccrine sweat duct: eccrine poroma, poroepithelioma and porocarcinoma. *Dermatologica* 1969; **138**: 238–250.
- Calonje E, Kazakov DV, Requena L, Harms PW. Porocarcinoma. *Skin tumours*. 5th ed. Lyon: World Health Organization Classification of Tumours, 2023.
- Scampa M, Merat R, Kalbermatten DF, Oranges CM. Head and neck Porocarcinoma: SEER analysis of epidemiology and survival. *J. Clin. Med.* 2022; **11**: 2185.
- Meriläinen A-S, Pukkala E, Böhling T, Koljonen V. Malignant eccrine porocarcinoma in Finland during 2007 to 2017. *Acta Derm. Venereol.* 2021; **101**: adv00363.
- Nazemi A, Higgins S, Swift R, In G, Miller K, Wysong A. Eccrine porocarcinoma: new insights and a systematic review of the literature. *Dermatol. Surg.* 2018; **44**: 1247–1261.
- Tripathi R, Ezaldein HH, Scott JF, Bordeaux JS. Trends in the incidence and survival of eccrine malignancies in the United States: a SEER population-based study. *J. Am. Acad. Dermatol.* 2019; **80**: 1769–1771.
- De Giorgi V, Silvestri F, Savarese I *et al.* Porocarcinoma: an epidemiological, clinical, and dermoscopic 20-year study. *Int. J. Dermatol.* 2022; **61**: 1098–1105.
- Kervarrec T, Frouin E, Collin C *et al.* Distinct regulations driving YAP1 expression loss in poroma, porocarcinoma and RB1-deficient skin carcinoma. *Histopathology* 2023; **82**(6): 885–898.
- Harms PW, Hovelson DH, Cani AK *et al.* Porocarcinomas harbor recurrent HRAS-activating mutations and tumor suppressor inactivating mutations. *Hum. Pathol.* 2016; **51**: 25–31.
- Bosic M, Kirchner M, Brasanac D *et al.* Targeted molecular profiling reveals genetic heterogeneity of poromas and porocarcinomas. *Pathology* 2018; **50**: 327–332.
- Sekine S, Kiyono T, Ryo E *et al.* Recurrent YAP1-MAML2 and YAP1-NUTM1 fusions in poroma and porocarcinoma. *J. Clin. Invest.* 2019; **129**: 3827–3832.
- Russell-Goldman E, Hornick JL, Hanna J. Utility of YAP1 and NUT immunohistochemistry in the diagnosis of porocarcinoma. *J. Cutan. Pathol.* 2021; **48**: 403–410.
- Prieto-Granada C, Morlote D, Pavlidakey P *et al.* Poroid adnexal skin tumors with YAP1 fusions exhibit similar histopathologic features: a series of six YAP1-rearranged adnexal skin tumors. *J. Cutan. Pathol.* 2021; **48**: 1139–1149.
- Snow JT, Georgantzoglou N, Green DC *et al.* Molecular analysis of NUT-positive poromas and porocarcinomas identifies novel break points of YAP1::NUTM1 fusions. *J. Cutan. Pathol.* 2022; **49**: 850–858.
- Agaimy A, Tögel L, Haller F, Zenk J, Hornung J, Märkl B. YAP1-NUTM1 gene fusion in porocarcinoma of the external auditory canal. *Head Neck Pathol.* 2020; **14**: 982–990.

19. Nishimura Y, Ryo E, Yamazaki N, Yatabe Y, Mori T. Cutaneous primary NUT carcinoma with BRD3-NUTM1 fusion. *Am. J. Surg. Pathol.* 2021; **45**: 1582–1584.
20. Kervarrec T, Amatore F, Pissaloux D et al. eds. Expanding the morphological Spectrum of primary cutaneous NUT carcinoma with BRD3-NUTM1 fusion. *Am. J. Surg. Pathol.* 2021; **45**(11): 1584–1586.
21. Rubio Gonzalez B, Ortiz MV, Ross DS, Busam KJ. Skin adnexal carcinoma with BRD3-NUTM2B fusion. *J. Cutan. Pathol.* 2021; **48**: 1508–1513.
22. Goldman P, Pinkus H, Rogin JR. Eccrine poroma; tumors exhibiting features of the epidermal sweat duct unit. *AMA Arch. Derm.* 1956; **74**: 511–521.
23. Winkelmann RK, McLeod WA. The dermal duct tumor. *Arch. Dermatol.* 1966; **94**: 50–55.
24. Zuger I. Basal-cell epitheliomas of the sole; a report of two cases. *AMA Arch. Derm.* 1957; **76**: 247–249.
25. Coburn JG, Smith JL. Hydroacanthoma simplex; an assessment of a selected group of intraepidermal basal cell epitheliomata and of their malignant homologues. *Br. J. Dermatol.* 1956; **68**: 400–418.
26. Horenstein MG, Sandoval MP, Lo Y, Jacob J. Holocrine poroma: a distinctive adnexal tumor. *Am. J. Dermatopathol.* 2018; **40**: 401–408.
27. Moreno-Vilchez C, Torrecilla-Vall-Llossera C, Llobera-Ris C, Muntaner-Virgili C, Penín RM, Marcoval J. Poroma: a retrospective series of 80 patients at a tertiary care hospital. *Actas Dermosifiliogr.* 2022; **114**: 102–107.
28. Battistella M, Langbein L, Peltre B, Cribier B. From hydroacanthoma simplex to poroid hidradenoma: clinicopathologic and immunohistochemic study of poroid neoplasms and reappraisal of their histogenesis. *Am. J. Dermatopathol.* 2010; **32**: 459–468.
29. WHO. In Elder, D.E., Massi, D., Scolyer, R.A., Willemze, R. eds. *WHO classification of skin tumours*. 4th ed. Lyon: International Agency for Research on Cancer, 2018. World Health Organization Classification of Tumours. SBN 978-92-832-2440-2.
30. Nguyen K, Kim G, Chiu M. Eccrine poromatosis following chemotherapy and radiation therapy. *Dermatol. Online J.* 2019; **25**: 13030/qt9177r4fp.
31. Choi EC-E, Lim JH-L. Eccrine poromatosis and polychemotherapy. *Int. J. Dermatol.* 2022; **61**: e132–e134.
32. Mahlberg MJ, McGinnis KS, Draft KS, Fakharzadeh SS. Multiple eccrine poromas in the setting of Total body irradiation and immunosuppression. *J. Am. Acad. Dermatol.* 2006; **55**: S46–S49.
33. Mehregan AH, Levson DN. Hydroacanthoma simplex. A report of two cases. *Arch. Dermatol.* 1969; **100**: 303–305.
34. Requena L, Sánchez M. Poroid hidradenoma: a light microscopic and immunohistochemical study. *Cutis* 1992; **50**: 43–46.
35. Miller AC, Adjei S, Temiz LA, Gill P, Siller A, Tyring SK. Dermal duct tumor: a diagnostic dilemma. *Dermatopathology (Basel)* 2022; **9**: 36–47.
36. Rütten A, Hantschke M, Angulo J, Requena L. Clear-cell dermal duct tumour: another distinctive, previously underrecognized cutaneous adnexal neoplasm. *Histopathology* 2007; **51**: 805–813.
37. Hu SCS, Chen GS, Wu CS, Chai CY, Chen WT, Lan CCE. Pigmented eccrine poromas: expression of melanocyte-stimulating cytokines by tumour cells does not always result in melanocyte colonization. *J. Eur. Acad. Dermatol. Venereol.* 2008; **22**: 303–310.
38. Salih AM, Kakamad FH, Baba HO et al. Porocarcinoma; presentation and management, a meta-analysis of 453 cases. *Ann Med Surg (Lond)* 2017; **20**: 74–79.
39. Tormo-Mainar S, Vidal J, Salido M, Pujol RM, Deza G. YAP1-NUTM1 gene fusion in eccrine porocarcinoma with late metastatic recurrence: a case report. *Acta Derm. Venereol.* 2022; **102**: adv00752.
40. Poiarés Baptista A, Tellechea O, Reis JP, Cunha MF, Figueiredo P. Eccrine porocarcinoma. A review of 24 cases. *Ann. Dermatol. Venereol.* 1993; **120**: 107–115.
41. Harms PW. Update on Merkel cell carcinoma. *Clin. Lab. Med.* 2017; **37**: 485–501.
42. Minowa T, Kamiya T, Hida T et al. Genetic analyses of a secondary poroma and trichoblastoma in a HRAS-mutated sebaceous nevus. *J. Dermatol.* 2021; **48**: 1268–1272.
43. Aslam A, Salam A, Griffiths CEM, McGrath JA. Naevus sebaceus: a mosaic RASopathy. *Clin. Exp. Dermatol.* 2014; **39**: 1–6.
44. Cribier B, Scrivener Y, Grosshans E. Tumors arising in nevus sebaceus: a study of 596 cases. *J. Am. Acad. Dermatol.* 2000; **42**: 263–268.
45. Hsu M-C, Liao J-Y, Hong J-L et al. Secondary neoplasms arising from nevus sebaceus: a retrospective study of 450 cases in Taiwan. *J. Dermatol.* 2016; **43**: 175–180.
46. Jaqueti G, Requena L, Sánchez Yus E. Trichoblastoma is the most common neoplasm developed in nevus sebaceus of Jadassohn: a clinicopathologic study of a series of 155 cases. *Am. J. Dermatopathol.* 2000; **22**: 108–118.
47. Macagno N, Kervarrec T, Sohier P et al. NUT is a specific immunohistochemical marker for the diagnosis of YAP1-NUTM1-rearranged cutaneous poroid neoplasms. *Am. J. Surg. Pathol.* 2021; **45**: 1221–1227.
48. Mitsui Y, Ogawa K, Goto K et al. YAP1::MAML2 fusions in poromatosis: a report of two patients. *J. Cutan. Pathol.* 2023; **50**: 695–701.
49. Chen L, Chan SW, Zhang X et al. Structural basis of YAP recognition by TEAD4 in the hippo pathway. *Genes Dev.* 2010; **24**: 290–300.
50. Kaneda A, Seike T, Danjo T et al. The novel potent TEAD inhibitor, K-975, inhibits YAP1/TAZ-TEAD protein-protein interactions and exerts an anti-tumor effect on malignant pleural mesothelioma. *Am. J. Cancer Res.* 2020; **10**: 4399–4415.
51. Yu F-X, Zhao B, Guan K-L. Hippo pathway in organ size control, tissue homeostasis, and cancer. *Cell* 2015; **163**: 811–828.
52. Szulzewsky F, Holland EC, Vasioukhin V. YAP1 and its fusion proteins in cancer initiation, progression and therapeutic resistance. *Dev. Biol.* 2021; **475**: 205–221.
53. Pearson JD, Huang K, Pacal M et al. Binary pan-cancer classes with distinct vulnerabilities defined by pro- or anti-cancer YAP/TEAD activity. *Cancer Cell* 2021; **39**: 1115–1134.e12.
54. Pajtlér KW, Witt H, Sill M et al. Molecular classification of ependymal tumors across all CNS compartments, histopathological grades, and age groups. *Cancer Cell* 2015; **27**: 728–743.
55. Sievers P, Chiang J, Schimpf D et al. YAP1-fusions in pediatric NF2-wildtype meningioma. *Acta Neuropathol.* 2020; **139**: 215–218.
56. Antonescu CR, Le Loarer F, Mosquera J-M et al. Novel YAP1-TFE3 fusion defines a distinct subset of epithelioid heman-gioendothelioma. *Genes Chromosomes Cancer* 2013; **52**: 775–784.

57. Puls F, Agaimy A, Flucke U *et al.* Recurrent fusions between YAP1 and KMT2A in morphologically distinct neoplasms within the Spectrum of low-grade fibromyxoid sarcoma and sclerosing epithelioid fibrosarcoma. *Am. J. Surg. Pathol.* 2020; **44**: 594–606.
58. Antonescu CR, Dickson BC, Sung Y-S *et al.* Recurrent YAP1 and MAML2 gene rearrangements in retiform and composite hemangioendothelioma. *Am. J. Surg. Pathol.* 2020; **44**: 1677–1684.
59. Szulzewsky F, Arora S, Hoellerbauer P *et al.* Comparison of tumor-associated YAP1 fusions identifies a recurrent set of functions critical for oncogenesis. *Genes Dev.* 2020; **34**: 1051–1064.
60. Kim J, Kwon H, Shin YK *et al.* MAML1/2 promote YAP/TAZ nuclear localization and tumorigenesis. *Proc. Natl Acad. Sci. USA* 2020; **117**: 13529–13540.
61. Sahebjam S, Gilbert MR. Modeling YAP fusions: a paradigm for investigating rare cancers? *Genes Dev.* 2022; **36**: 874–875.
62. Picco G, Chen ED, Alonso LG *et al.* Functional linkage of gene fusions to cancer cell fitness assessed by pharmacological and CRISPR-Cas9 screening. *Nat. Commun.* 2019; **10**: 2198.
63. Kuma Y, Yamada Y, Yamamoto H *et al.* A novel fusion gene CRTC3-MAML2 in hidradenoma: histopathological significance. *Hum. Pathol.* 2017; **70**: 55–61.
64. Winnes M, Mölne L, Suurküla M *et al.* Frequent fusion of the CRTC1 and MAML2 genes in clear cell variants of cutaneous hidradenomas. *Genes Chromosomes Cancer* 2007; **46**: 559–563.
65. French CA, Miyoshi I, Kubonishi I, Grier HE, Perez-Atayde AR, Fletcher JA. BRD4-NUT fusion oncogene: a novel mechanism in aggressive carcinoma. *Cancer Res.* 2003; **63**: 304–307.
66. Kitagawa M. Notch signalling in the nucleus: roles of mastermind-like (MAML) transcriptional coactivators. *J. Biochem.* 2016; **159**: 287–294.
67. Dermawan JK, Westra WH, Antonescu CR. Recurrent PTBP1::MAML2 fusions in composite hemangioendothelioma with neuroendocrine differentiation: a report of two cases involving neck lymph nodes. *Genes Chromosomes Cancer* 2022; **61**: 187–193.
68. Perret R, Tallegas M, Velasco V *et al.* Recurrent YAP1::MAML2 fusions in 'nodular necrotizing' variants of myxoinflammatory fibroblastic sarcoma: a comprehensive study of 7 cases. *Mod. Pathol.* 2022; **35**: 1398–1404.
69. Chen Z, Ni W, Li J-L *et al.* The CRTC1-MAML2 fusion is the major oncogenic driver in mucoepidermoid carcinoma. *JCI Insight* 2021; **6**: e139497.
70. Zhao J, Zhao R, Xiang C, Shao J, Guo L, Han Y. YAP1-MAML2 fusion as a diagnostic biomarker for metaplastic thymoma. *Front. Oncol.* 2021; **11**: 692283.
71. Tauziède-Espariat A, Siegfried A, Nicaise Y *et al.* A novel YAP1-MAML2 fusion in an adult supra-tentorial ependymoma, YAP1-fused. *Brain Tumor Pathol.* 2022; **39**: 240–242.
72. Menu E, Beaufils N, Usseglio F *et al.* First case of B ALL with KMT2A-MAML2 rearrangement: a case report. *BMC Cancer* 2017; **17**: 363.
73. Wu L, Liu J, Gao P *et al.* Transforming activity of MECT1-MAML2 fusion oncoprotein is mediated by constitutive CREB activation. *EMBO J.* 2005; **24**: 2391–2402.
74. Tonon G, Modi S, Wu L *et al.* T(11;19)(Q21;P13) translocation in mucoepidermoid carcinoma creates a novel fusion product that disrupts a notch signaling pathway. *Nat. Genet.* 2003; **33**: 208–213.
75. Shiota H, Barral S, Buchou T *et al.* Nut directs P300-dependent, genome-wide H4 hyperacetylation in male germ cells. *Cell Rep.* 2018; **24**: 3477–3487.e6.
76. Kubonishi I, Takehara N, Iwata J *et al.* Novel t(15;19)(Q15;P13) chromosome abnormality in a thymic carcinoma. *Cancer Res.* 1991; **51**: 3327–3328.
77. French CA, Ramirez CL, Kolmakova J *et al.* BRD-NUT oncoproteins: a family of closely related nuclear proteins that block epithelial differentiation and maintain the growth of carcinoma cells. *Oncogene* 2008; **27**: 2237–2242.
78. French CA, Rahman S, Walsh EM *et al.* NSD3-NUT fusion oncoprotein in NUT midline carcinoma: implications for a novel oncogenic mechanism. *Cancer Discov.* 2014; **4**: 928–941.
79. Le Loarer F, Pissaloux D, Watson S *et al.* Clinicopathologic features of CIC-NUTM1 sarcomas, a new molecular variant of the family of CIC-fused sarcomas. *Am. J. Surg. Pathol.* 2019; **43**: 268–276.
80. Diolaiti D, Dela Cruz FS, Gundem G *et al.* A recurrent novel MGA-NUTM1 fusion identifies a new subtype of high-grade spindle cell sarcoma. *Cold Spring Harb. Mol. Case Stud.* 2018; **4**: a003194.
81. Luo W, Stevens TM, Stafford P, Miettinen M, Gatalica Z, Vranic S. NUTM1-rearranged neoplasms—a heterogeneous group of primitive tumors with expanding spectrum of histology and molecular alterations—an updated review. *Curr. Oncol.* 2021; **28**: 4485–4503.
82. Schwartz BE, Hofer MD, Lemieux ME *et al.* Differentiation of NUT midline carcinoma by epigenomic reprogramming. *Cancer Res.* 2011; **71**: 2686–2696.
83. Reynoird N, Schwartz BE, Delvecchio M *et al.* Oncogenesis by sequestration of CBP/P300 in transcriptionally inactive hyperacetylated chromatin domains. *EMBO J.* 2010; **29**: 2943–2952.
84. Macagno N, Pissaloux D, de La Fouchardiere A *et al.* Wholistic approach – transcriptomic analysis and beyond using archival material for molecular diagnosis. *Genes Chromosomes Cancer* 2022; **61**(6): 382–393.
85. Kervarrec T, Pissaloux D, Paindavoine S *et al.* Recurrent PAK2 rearrangements in poroma with folliculo-sebaceous differentiation. *Histopathology* 2023; **83**: 310–319.
86. Thibodeau ML, Bonakdar M, Zhao E *et al.* Whole genome and whole transcriptome genomic profiling of a metastatic eccrine porocarcinoma. *NPJ Precis. Oncol.* 2018; **2**: 8.
87. Walter BN, Huang Z, Jakobi R *et al.* Cleavage and activation of P21-activated protein kinase gamma-PAK by CPP32 (caspase 3). Effects of autophosphorylation on activity. *J. Biol. Chem.* 1998; **273**: 28733–28739.
88. Sero JE, Bakal C. Multiparametric analysis of cell shape demonstrates that β-PIX directly couples YAP activation to extracellular matrix adhesion. *Cell Syst.* 2017; **4**: 84–96.e6.
89. Kervarrec T, Pissaloux D, Paindavoine S *et al.* Recurrent PAK2 rearrangements in apocrine poroma. *Histopathology* 2023; **83**(2): 310–319.
90. Chen JF, Yan Q. The roles of epigenetics in cancer progression and metastasis. *Biochem. J.* 2021; **478**: 3373–3393.
91. Ferrari A, Iannó MF, Carenzo A *et al.* Complexity index in sarcoma and genomic grade index gene signatures in rhabdomyosarcoma of pediatric and adult ages. *Pediatr. Blood Cancer* 2021; **68**: e28987.
92. Chibon F, Lesluyes T, Valentin T, Le Guellec S. CINSARC signature as a prognostic marker for clinical outcome in sarcomas and beyond. *Genes Chromosomes Cancer* 2019; **58**: 124–129.

93. Bertucci F, De Nonneville A, Finetti P *et al.* The genomic grade index predicts postoperative clinical outcome in patients with soft-tissue sarcoma. *Ann. Oncol.* 2018; **29**: 459–465.
94. Denisova E, Westphal D, Surowy HM *et al.* Whole-exome sequencing in eccrine porocarcinoma indicates promising therapeutic strategies. *Cancer Gene Ther.* 2021; **29**: 697–708.
95. Stelow EB, Bellizzi AM, Taneja K *et al.* NUT rearrangement in undifferentiated carcinomas of the upper aerodigestive tract. *Am. J. Surg. Pathol.* 2008; **32**: 828–834.
96. McColl K, Wildey G, Sakre N *et al.* Reciprocal expression of INSM1 and YAP1 defines subgroups in small cell lung cancer. *Oncotarget* 2017; **8**: 73745–73756.
97. Asrani K, Torres AF, Woo J *et al.* Reciprocal YAP1 loss and INSM1 expression in neuroendocrine prostate cancer. *J. Pathol.* 2021; **255**: 425–437.
98. Lazo de la Vega L, Bick N, Hu K *et al.* Invasive squamous cell carcinomas and precursor lesions on UV-exposed epithelia demonstrate concordant genomic complexity in driver genes. *Mod. Pathol.* 2020; **33**: 2280–2294.
99. Kervarrec T, Tallet A, Macagno N *et al.* Sweat gland tumors arising on acral sites: a molecular survey. *Am. J. Surg. Pathol.* 2023. <https://doi.org/10.1097/PAS.0000000000002098>
100. Chau NG, Ma C, Danga K *et al.* An anatomical site and genetic-based prognostic model for patients with nuclear protein in testis (NUT) midline carcinoma: analysis of 124 patients. *JNCI Cancer Spectr.* 2020; **4**: pkz094.
101. Wang Z, Li Y, Banerjee S, Sarkar FH. Emerging role of notch in stem cells and cancer. *Cancer Lett.* 2009; **279**: 8–12.