



## Irreversible malarial retinopathy in a returning adult traveler to Marseille, France

Amadou Daye Diallo, Victor Desfeux, Natacha Stolowy, Coralie L'Ollivier, Emilie Javelle, Thierry David, Nadim Cassir

### ► To cite this version:

Amadou Daye Diallo, Victor Desfeux, Natacha Stolowy, Coralie L'Ollivier, Emilie Javelle, et al.. Irreversible malarial retinopathy in a returning adult traveler to Marseille, France. *Travel Medicine and Infectious Disease*, 2023, 55, pp.102643. 10.1016/j.tmaid.2023.102643 . hal-04279285

**HAL Id: hal-04279285**

**<https://amu.hal.science/hal-04279285>**


Submitted on 16 Feb 2024

**HAL** is a multi-disciplinary open access archive for the deposit and dissemination of scientific research documents, whether they are published or not. The documents may come from teaching and research institutions in France or abroad, or from public or private research centers.

L'archive ouverte pluridisciplinaire **HAL**, est destinée au dépôt et à la diffusion de documents scientifiques de niveau recherche, publiés ou non, émanant des établissements d'enseignement et de recherche français ou étrangers, des laboratoires publics ou privés.



Distributed under a Creative Commons Attribution 4.0 International License



## Irreversible malarial retinopathy in a returning adult traveler to Marseille, France

## ARTICLE INFO

## Keywords

Malaria  
Retinal ischemia  
Cerebral malaria  
Malarial retinopathy  
*Plasmodium falciparum*  
Travel medicine

Dear Editor,

Cerebral malaria (CM) is one of the major manifestations of severe malaria, and a leading cause of malaria mortality with a 15–20% fatality rate. The development of CM may occur in 1% of children infected with *Plasmodium falciparum*, and is much more common in children under 5 years living in endemic area, than among non-migrant travelers, adults especially [1]. In France, 2,800 cases of imported malaria were recorded in 2022, of whom 18% were severe, 5% had CM and 0.3% were fatal (French National Reference Center for malaria data). Importantly, neurological signs of CM are not specific and people living in endemic areas often host parasites at subclinical levels. Over there, the definitive diagnosis of CM may significantly be improved through the observation of malaria-specific retinopathy (RP), that can serve as a diagnostic and prognostic criteria for CM [1].

We report a 56-year-old female case of CM with RP. She originated from Cameroon but had been living in France for more than 10 years. She had a history of high blood pressure and chronic alcoholism and had returned in January 2022 from a 2-month stay in Cameroon. She had not taken anti-malarial chemoprophylaxis and had travelled to forest areas. Two weeks after her return to France, she was brought to the emergency department in Marseille, for a febrile loss of consciousness. The clinical examination revealed a Glasgow Coma Scale score of 10/15 and conjunctival jaundice. The diagnosis of severe *Plasmodium falciparum* malaria infection was confirmed by rapid molecular detection test (LAMP technique) and peripheral blood thin smear finding 4.3% of infected red blood cells. The smear was read at lower magnification and fortuitously showed a microfilaria with a density of 40 microfilariae/ml, further identified as *Loa loa* by PCR [2]. She was hospitalized in the intensive care unit and treated with intravenous artesunate for 3 days. On the third day, parasitaemia was 0.05% and the patient was transferred to the infectious diseases department starting a 3-day oral relay with dihydroartemisinin-piperaquine. Loiasis was subsequently treated with diethylcarbamazine at increasing doses for a duration of 21 days. Microfilaremia was negative on day 7. The clinical examination found a bilateral visual blurring and persistent temporospatial disorientation. Blood smears were negative 7 and 28 days after the antimalarial

treatment. Cerebrospinal fluid (CSF) analysis revealed 6 lymphocytes/mm<sup>3</sup>. Brain MRI showed vascular-like leukopathy and diffuse dilation of Virchow Robin's spaces, without significant cortical or hippocampal atrophy. The ophthalmological examination found visual acuity collapsed to 6/10 in the right eye, a calm anterior chamber. Fundoscopy revealed multiple hemorrhages in clear center and cotton wool spots bilaterally; a large area of central retinal ischemia with nasal foveolar sparing and a small retro-hyaloid hemorrhage (right); a patch of central retinal ischemia with nasal foveolar sparing (left) concluding in bilateral occlusive vasculitis (Fig. 1A). Fluorescein angiography confirmed retinal hemorrhage by mask effect and areas of ischemia (Fig. 1B). Although the patient recovered from disorders of consciousness, there was no improvement of retinal lesions at one-year follow-up.

Malaria and loiasis are significant vector-borne diseases that are frequently co-endemic. The overall prevalence of malaria and loiasis co-infection was 1.2% in a recent meta-analysis [3]. The highest prevalence was found in Cameroon (2.7%). Unlike the present case, patients with co-infections usually have lower malarial parasite density, and more asymptomatic clinical status, when compared to malaria mono-infection [3]. Moreover, ocular signs of loiasis are significantly different from malaria. They include painful periorbital swelling, where the worm may present both in the subconjunctival compartment or in the anterior chamber, whereas ophthalmological malaria typically involves the retina. Exceptionally, unilateral retinal artery occlusion has been associated with the persistent presence of *Loa loa* microfilaremia in the bloodstream [4].

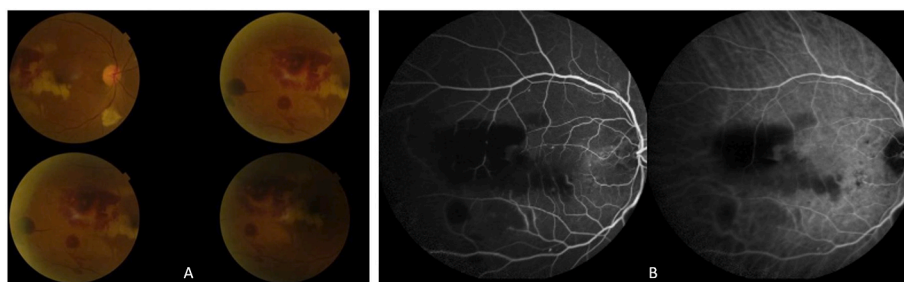
Malarial retinopathy is defined by the occlusion of the vessels of the retinal microcirculation secondary to the sequestration of parasitized red blood cells. Retinal hemorrhage correlates with disease severity. Moderate RP may also be found occasionally in patients with uncomplicated *P. falciparum* or *P. vivax* malaria [5]. It was first described in 1878 by Poncet who noted that almost all cases of 'pernicious malaria' were accompanied by retinal hemorrhages. Retinal whitening (macula whitening sparing central fovea and peripheral whitening of the fundus) that we observed in the case presented here, is considered as one of the specific symptoms of CM, and therefore can help differentiate malaria from other causes of coma and fever before microbiological

<https://doi.org/10.1016/j.tmaid.2023.102643>

Received 4 September 2023; Received in revised form 9 September 2023; Accepted 17 September 2023

Available online 19 September 2023

1477-8939/© 2023 The Authors. Published by Elsevier Ltd. This is an open access article under the CC BY-NC-ND license (<http://creativecommons.org/licenses/by-nc-nd/4.0/>).



**Fig. 1.** A. Right fundus. Hemorrhages, Roth spots and retinal bleaching secondary to ischemia by sequestration. B. Fluorescein angiography of the right eye identifying ischemic and hemorrhagic lesions.

confirmation. Data on malarial RP outcomes are scarce. Beare et al. showed in a study in which 116 children with CM were followed up longitudinally by fundus ophthalmoscopy that in those who survived, retinal signs resolved over 1–4 weeks without retinal sequelae [6]. But, in African children survivors of CM, neurological sequelae are more frequent in retinopathy-positive cases, approaching approximately 30% [1]. Few cases of malarial RP reversibility have been reported in adults [7]. Future research is needed to better understand vascular changes in malarial RP, their prognostic significance, and targets for earlier intervention with adjunctive therapies.

### Ethical declaration

Written informed consent was obtained from the patient.

### Sources of funding

None to declare.

### Declaration of competing interest

None to declare.

### References

- [1] Luzolo AL, Ngoyi DM. Cerebral malaria. *Brain Res Bull* 2019;145:53–8. <https://doi.org/10.1016/j.brainresbull.2019.01.010>.
- [2] Menu E, Girardet F, Cassir N, L'Ollivier C. Dual infection: what diptera has (have) bit her. *Trav Med Infect Dis* 2022;49:102380. <https://doi.org/10.1016/j.tmaid.2022.102380>.
- [3] Wilairatana P, Kotepui KU, Mala W, Wangdi K, Kotepui M. Prevalence, probability, and characteristics of malaria and filariasis co-infections: a systematic review and meta-analysis. *PLoS Neglected Trop Dis* 2022;16:e0010857. <https://doi.org/10.1371/journal.pntd.0010857>.
- [4] Hemilembolo MC, Niama AC, Campillo JT, Pion SD, Missamou F, Whittaker C, et al. Excess mortality associated with loiasis: confirmation by a new retrospective cohort study conducted in the Republic of Congo. *Open Forum Infect Dis* 2023;10:ofad103. <https://doi.org/10.1093/ofid/ofad103>.
- [5] Padhy SK, Sahu S, Govindahari V. Retinopathy secondary to uncomplicated Plasmodium vivax malaria. *Ophthalmic Surg Lasers Imaging Retina* 2021;52:50–1. <https://doi.org/10.3928/23258160-20201223-10>.
- [6] Beare NA, Southern C, Chalira C, Taylor TE, Molyneux ME, Harding SP. Prognostic significance and course of retinopathy in children with severe malaria. *Arch Ophthalmol* 2004;122:1141–7. <https://doi.org/10.1001/archophth.122.8.1141>.
- [7] Maude RJ, Kingston HWF, Joshi S, Mohanty S, Mishra SK, White NJ, et al. Reversibility of retinal microvascular changes in severe falciparum malaria. *Am J Trop Med Hyg* 2014;91:493–5. <https://doi.org/10.4269/ajtmh.14-0116>.

Amadou Daye Diallo<sup>1</sup>

IHU-Méditerranée Infection, Marseille, France

Aix Marseille Univ, IRD, AP-HM, SSA, VITROME, Marseille, France

Victor Desfeux<sup>1</sup>, Natacha Stollowy

Ophthalmology Department, AP-HM, Marseille, France

Coralie L'Ollivier

IHU-Méditerranée Infection, Marseille, France

Aix Marseille Univ, IRD, AP-HM, SSA, VITROME, Marseille, France

Emilie Javelle

IHU-Méditerranée Infection, Marseille, France

Aix Marseille Univ, IRD, AP-HM, SSA, VITROME, Marseille, France

Centre National de Référence du Paludisme, Marseille, 13005, France

Unité Parasitologie et Entomologie, Département Microbiologie et Maladies

Infectieuses, Institut de Recherche Biomédicale des Armées (IRBA),

Marseille, 13005, France

Thierry David

Ophthalmology Department, AP-HM, Marseille, France

Nadim Cassir\*

IHU-Méditerranée Infection, Marseille, France

Aix Marseille Univ, IRD, AP-HM, MEPHI, Marseille, France

\* Corresponding author. MEPHI, Institut Hospitalo-Universitaire Méditerranée Infection, 19–21 Boulevard Jean Moulin, 13005, Marseille, France.

E-mail address: [nadimshams.cassir@ap-hm.fr](mailto:nadimshams.cassir@ap-hm.fr) (N. Cassir).

<sup>1</sup> Contributed equally.