



HAL
open science

Brain FDG-PET correlates of saccadic disorders in early PSP

G. Pin, J. Labouré, E. Guedj, O. Felician, S. Grimaldi, J. Azulay, M. Ceccaldi, L. Koric

► **To cite this version:**

G. Pin, J. Labouré, E. Guedj, O. Felician, S. Grimaldi, et al.. Brain FDG-PET correlates of saccadic disorders in early PSP. *Journal of Neurology*, 2023, 270 (10), pp.4841-4850. 10.1007/s00415-023-11824-w . hal-04406600

HAL Id: hal-04406600

<https://amu.hal.science/hal-04406600v1>

Submitted on 14 Apr 2024

HAL is a multi-disciplinary open access archive for the deposit and dissemination of scientific research documents, whether they are published or not. The documents may come from teaching and research institutions in France or abroad, or from public or private research centers.

L'archive ouverte pluridisciplinaire **HAL**, est destinée au dépôt et à la diffusion de documents scientifiques de niveau recherche, publiés ou non, émanant des établissements d'enseignement et de recherche français ou étrangers, des laboratoires publics ou privés.

Brain FDG-PET correlates of saccadic disorders in early PSP

G.Pin¹, J.Labouré¹, E.Guedj^{2,3,4}, O.Felician¹, S.Grimaldi⁵, JP.Azulay⁵, M.Ceccaldi¹, L.Koric^{1,4}

¹ Department of Neurology and Neuropsychology, and CMMR PACA Ouest, CHU Timone, Assistance Publique Hôpitaux de Marseille, Marseille, France

² Department of Nuclear Medecine, CHU Timone, Assistance Publique Hôpitaux de Marseille, Marseille, France

³ CERIMED, Aix-Marseille Univ, Marseille, France

⁴ Aix-Marseille Univ, UMR 7249, CNRS, Centrale Marseille, Institut Fresnel, Marseille, France

⁵ Department of Neurology and Movement Disorders, CHU Timone, Assistance Publique Hôpitaux de Marseille, Marseille, France

Abstract

Background: New diagnostic criteria of progressive supranuclear palsy (PSP) have highlighted the interest of eye movement records (EMR) at the early stage of the disease.

Objectives: To investigate the metabolic brain correlates of ocular motor dysfunction using [18F] fluorodeoxyglucose positron emission tomography (FDG-PET) in early PSP.

Methods: Retrospective observational descriptive study on longitudinal data with patients who underwent EMR and FDG-PET at the stage of suggestive and possible PSP according to movement disorders society (MDS) criteria. Longitudinal follow-up enables to confirm diagnosis of probable PSP. Using the Statistical Parametric Mapping software (SPM), we performed whole-brain voxel-based correlations between oculomotor variables and FDG-PET metabolism.

Results: Thirty-seven patients with early PSP who fulfilled criteria of probable PSP during the follow-up were included. Decrease in the gain of vertical saccades correlated with reduced metabolism in superior colliculi (SC). We also found a positive correlation between mean velocity of horizontal saccades and SC metabolism as well as dorsal nuclei in the pons. Finally, increase in horizontal saccades latencies correlated with decrease of posterior parietal metabolism.

Conclusions: These findings suggest the early involvement of SC in saccadic dysfunction in the course of PSP.

Keywords: progressive supra nuclear palsy – eye movement analysis – fluorodeoxyglucose positron emission tomography – atypical parkinsonism

Statements and declarations

Declarations of interest: The authors declare that they have no conflict of interest.

Introduction

Progressive supranuclear palsy (PSP) was first described by Steele, Richardson and Olszewski in 1963 as a progressive neurodegenerative disorder pathologically characterized by neuronal loss, granulovacuolar degeneration, gliosis and neurofibrillary tangles in the basal ganglia, brainstem and cerebellar nuclei [1,2]. The classical presentation of PSP associates a predominantly axial parkinsonism, supranuclear gaze palsy and postural instability with early falls. Over the past decade, accumulating clinicopathological evidence has led to the description of additional clinical subtypes with cognitive, language and behavioral symptoms associated with PSP-pathology. This also raised differential diagnosis issues with other neurodegenerative diseases and pathological examination remains the gold standard for a definite diagnosis. To improve clinical diagnosis, the movement disorder society established new diagnostic criteria (MDS-PSP criteria) based on clinicopathological studies [3,4]. Accordingly, oculomotor dysfunction is considered as the best clinical feature [5].

Different procedures are used to study eye movements. Video oculography (VOG) is a non-invasive and well-established technique to measure and quantify oculomotor parameters [6]. Several groups have demonstrated the usefulness of VOG in investigating atypical parkinsonian syndromes, in particular in establishing specific ocular motor characteristics of PSP [7,8]. Abnormal saccades have been evidenced early in the course of the disease. Slow and small saccades are the disease's hallmark and are considered as the most specific oculomotor features in PSP when compared to other atypical parkinsonian syndromes and frontotemporal lobar degeneration (FTLD) [5,9]. Decrease in peak saccade velocity (V_{max}) is classically attributed to the loss of mesencephalic saccadic burst generators from Rostral Interstitial Nucleus of the Medial Longitudinal Fasciculus (riMLF). Neuropathological and imaging findings demonstrate abnormalities and typical atrophy of the mesencephalon showing the characteristic "hummingbird" appearance [10]. In addition, some authors have speculated that the superior colliculi (SC), as an important regulator of inhibitory and excitatory burst inputs, may also significantly contribute to saccade slowing at the beginning of the disease [7].

To our knowledge, the relationship of saccade parameters and functional brain substrates at early stages of the disease has not been yet fully addressed. In a [18F] fluorodeoxyglucose positron emission tomography (FDG-PET) study performed on patients with PSP, most (18 out of 26) fulfilling consensus criteria for "possible or probable PSP" in use at the time of study, Amstage *et al.* described the association between downward palsy and hypometabolism in the anterior cingulate gyrus [11]. However, these results are ambiguous regarding neural correlates of saccadic system and common neuropathological features observed in PSP, particularly when considering that no correlations are observed between vertical gaze palsy and brain metabolism in midbrain and brainstem regions. The

small sample size of PSP patients in this study and their clinical heterogeneity, in particular subjects with advanced stage disease, may have accounted for these findings.

Therefore, the present study aims to measure the correlations between clinical data obtained from analyses of saccadic records using VOG and regional cerebral glucose metabolism to map the metabolic neural correlates of ocular motor abnormalities in PSP patients at early stage of the disease. We analyzed data obtained from VOG records and FDG-PET brain imaging in a retrospective clinical population of patients with PSP at early course of the disease. The cohort corresponds to patients who presented with clinical features of “suggestive PSP” or “possible PSP” according to MDS-PSP criteria. We hypothesized that abnormal saccades parameters such as slowness and/or reduced accuracy would be correlated with reduced brain metabolism in brainstem, in particular in SC, suggesting its role in early oculomotor alterations in PSP.

Methodology

Design study

Retrospective observational descriptive monocentric study conducted at the University Hospital of Marseille, based on longitudinal data.

Patients' selection (Fig.1)

All patients included in the study have been referred to two tertiary care departments, either the Department of Neurology and Neuropsychology and the department of Neurology and Movement Disorders of Timone Hospital (AP-HM). All data were collected from the routine clinical practice and research was performed from retrospectively collected data. Considered as a non-interventional study according to French legislation, our study was approved by a local expert ethical comity for research study (PADS22-37).

To select patients with PSP at early stages among all those referred to our center, we screened records of all patients who consulted for an atypical parkinsonian syndrome and/or cognitive/speech or behavior disorder between 1st January 2015 and 31th December 2020, and who had performed an interpretable Eye Movement Records using VOG (EMR-VOG). To suit to the objective of study in which an early identification of PSP individuals was required and the diagnosis confirmed as the disease evolves, we excluded all patients with a diagnosis of probable PSP established at the time of EMR-VOG. We also excluded patients with other brain comorbidities and patients who performed EMR-VOG for other conditions. In addition, patients with missing clinical data at the time of EMR-VOG were excluded (see *data collection*). Therefore, all selected patients fulfilled the criteria for “suggestive” PSP” or

“possible” PSP according to MDS-PSP consensus criteria [5]. “Suggestive PSP” and “possible PSP” represent subtle and/or early signs of PSP, but do not meet the threshold for probable PSP [5]. Thus, patients who were eligible for selection were those with i) isolated poorly or non-L-Dopa responsive parkinsonian syndrome, ii) mild cognitive or behavior disorders of executive type associated or not with clinical parkinsonism, iii) speech disorders (dysarthria or apraxia of speech), iv) isolated vertical supranuclear palsy on clinical examination before EMR. The longitudinal follow-up allowed to establish diagnosis of probable PSP. As the aim of our study was to establish EMR-VOG- brain metabolism correlations, patients without available PET-FDG imaging were also excluded. Therefore, only were retained for further analysis 37 patients for whom a diagnosis of probable PSP was established during the follow up period by a multidisciplinary clinical team that included at least two experienced neurologists. It is noteworthy that the diagnosis of probable PSP was achieved independently of initial FDG-PET imaging and EMR-VOG results. MAX rules were used to manage the multiple allocations problem.

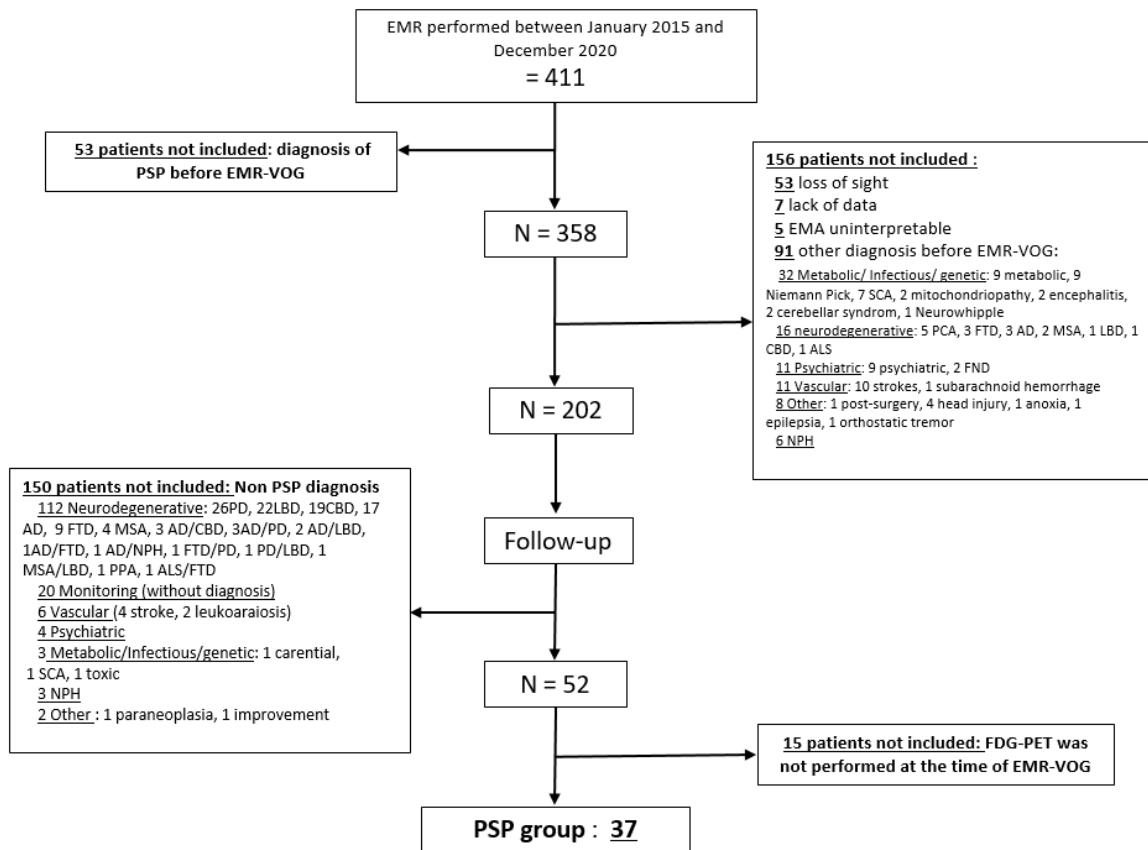


Fig.1 Flow chart. EMR: eye movements records (by video-oculographic recording); PSP: progressive supra-nuclear palsy; SCA: autosomal dominant spinocerebellar ataxias, PCA: posterior cortical atrophy, FTD: fronto-temporal dementia, AD: Alzheimer’s disease, MSA: multi-systemic atrophy, LBD: Lewy body disease, CBD: cortico-basal degeneration, ALS: amyotrophic lateral sclerosis, PPA: primary progressive aphasia, PD: idiopathic Parkinson’s disease.

Data collection

Clinical data were extracted from the patients’ records (hospitalization and consultation reports). We analyzed clinical characteristics of the patients prior to EMR-VOG and FDG-PET performances. For the correlation with FDG-PET, we retained data from VOG records for horizontal and vertical saccades. Oculomotor parameters that were correlated with FDG-PET cerebral metabolism were mean and peak velocity, latency, gain and the rate of error of anti-saccade (see *Video-Oculography* for details).

FDG-PET

FDG-PET is not mandatory for PSP diagnosis in the MDS-PSP criteria. However, it has recently been suggested that results from FDG-PET imaging could contribute to PSP diagnosis [12]. Moreover, in our tertiary care department, patients with atypical presentations of neurodegenerative diseases (atypical Parkinsonism or frontal lobe type behavioral /cognitive changes) usually undergo an extensive work-up including EMR and FDG-PET examination. In consequence, many patients benefited from this procedure early in the diagnostic process.

FDG-PET brain scans were acquired in the same center using an acquisition protocol conforming to European guidelines, at resting-state, in subjects fasting for at least 4h with a controlled, normal glycemic level, using an integrated PET/CT General Electric camera (Waukesha, WI), after an intravenous administration of 111 MBq per 15-min acquisition at 30min post-injection. Images were reconstructed on a 192×192 matrix using the ordered subsets expectation maximization algorithm and corrected for attenuation using a CT transmission scan. Whole-brain statistical analysis was performed at the voxel-level using the Statistical Parametric Mapping 8 software (SPM) (Wellcome Department of Cognitive Neurology, University College, London, UK) to study correlation between metabolism and oculomotor features (*see the video-oculography part: Vmean, Vmax latency and gain of pro saccades and error rate of anti-saccades*), in addition to age and sex **as covariates of no interest**. The PET images were spatially normalized onto the Montreal Neurological Institute (MNI) atlas. The dimensions of the resulting voxels were 2×2×2 mm. The images were then smoothed with a Gaussian filter (8 mm full-width at half-maximum) to blur individual variations in the gyral anatomy and to increase the signal-to-noise ratio. Proportional scaling was performed to give the same global metabolic value to each PET examination. Voxel-based analyses were limited within a mask including the brain grey-matter, the cerebellum and the brainstem, using WFU_PickAtlas (https://www.nitrc.org/projects/wfu_pickatlas/). The SPM(T) PET maps were first obtained at an uncorrected height threshold (voxel-level significance) of $p < 0.001$, and a corrected p-value for the cluster size of $p < 0.05$ using FWE-method (family-wise error). In absence of significant findings and in the hypothesis of brainstem involvement, the SPM(T) PET maps were secondarily obtained at an uncorrected height threshold (voxel-level significance) of $p < 0.005$, with a small volume correction for the cluster at the level of the brainstem with a sphere of 12mm-radius for p-value corrected both for the voxel and cluster at $p < 0.05$ (FWE).

Video-Oculography

EMR-VOG analysis were performed using the recording system EyeBRAIN® tracker, distributed by SURICOG with a 21-inch screen (resolution of 1920 x 1080 pixels). The automatic analysis was performed by EyeBRAIN® meveParadigm and meyeAnalysis software (version 1.18.1) which allow automatic recording (binocular mode, acquisition frequency of 300 Hz, spatial accuracy of 0.5°) and

analysis of various parameters of pro-saccade tests (vertical and horizontal saccades). Each sequence contained 12 saccades, each one ending with the return on the central fixation point. Each self-coded saccades sequence was checked manually. Mean (V_{mean}) and maximum (V_{max}) velocities of horizontal and vertical pro-saccades, their latencies and their gain were collected for each trial and for each patient. The gain of saccade (saccade amplitude/target amplitude) is the usual measure of their accuracy. Trials with latencies less than 75ms or greater than 800ms were excluded to avoid artifacts related to anticipated saccades or randomized responses. The percentage of error in anti-saccades was also assessed. All the EMR-VOG were performed by the same operator.

Statistics

Subjects' characteristics are described as means and standard deviations for continuous variables, and frequencies or percentages for categorical variables.

Results

Patients

Data collection resulted in the selection of a group of 37 patients with early PSP. Patient's characteristics, clinical subtypes and features are summarized in Table 1. Data were collected from patients' clinical records at baseline and at follow up. Oculomotor findings are those obtained at bedside testing by the clinician (before EMR-VOG). It is noteworthy that PET-FDG and EMR-VOG were performed in the same timeframe.

Patients characteristics	Mean (+/SD)			
Sex ratio (W/M)	13/24			
Age at occurrence of first symptoms (year)	68.11	(+/- 4.40)		
Age at first consultation (year)	71.99	(+/- 6.45)		
Age at PET acquisition (year)	72.61	(+/- 5.79)		
Age at EMR (year)	72.97	(+/- 5.74)		
Age at diagnosis (year)	73.73	(+/- 5.37)		
First complaints-PET-FDG interval (year)	4.50	(+/- 2.89)		
First complaints-EMR interval (year)	4.86	(+/- 3.81)		
First complaints-diagnosis interval (year)	5.62	(+/- 3.88)		
Clinical subtypes and features (max rules)	Baseline	(%)	Follow-up	(%)
Probable PSP-RS			16	(43.24)
Probable PSP-P			16	(43.24)
Probable PSP-PGF	-		3	(8.11)
Probable PSP-F	-		2	(5.44)
Possible PSP-PGF	6	(16.22)	-	-
Suggestive PSP-P	16	(43.24)	-	-
Suggestive PSP-PI	13	(37.84)	-	-
Suggestive PSP-SL	1	(2.70)	-	-
Suggestive PSP-OM	1	(2.70)	-	-
O1 Vertical supranuclear palsy	1	(2.70)	6	(16.22)
O2 Slow velocity of vertical saccade (bed side testing)	5		31	(83.78)
O3 Square waves or apraxia of eye opening (bed side testing)	0		9	(24.32)
P1p2 Falls	18	(48.65)	19	(51.35)
P3 Alteration of postural reflex	25	(67.57)	26	(70.27)
A1 Progressive freezing	6	(16.22)	6	(16.22)
A2 Axial akineto-rigid parkinsonian syndrome	29	(78.38)	29	(78.38)
A3 Parkinsonism	26	(70.27)	27	(72.97)
C1 Non fluent PPA or speech/language disorder)	1	(2.70)	3	(8.11)
C2 Frontal cognitive or behavioral syndrome	34	(91.89)	35	(94.59)
Apathy	13	(35.14)	13	(35.14)
Bradyphrenia	20	(54.05)	21	(56.76)
Dysexecutive syndrome	23	(62.16)	23	(62.16)
Reduced phonemic verbal fluency	12	(32.43)	12	(32.43)
Impulsivity, disinhibition, or perseveration	9	(24.32)	10	(27.03)
C3 Corticobasal syndrome	5	(13.51)	5	(13.51)
CC1 Doparesistance	11/14	(29.73)	13/14	(35.14)
CC2 Dysarthria	8	(21.62)	8	(21.62)
CC3 Dysphagia	6	(16.22)	7	(18.92)
CC4 Photophobia	0		0	

Table.1 Population (N=37) characteristics with MAX rules [20] applied according to criteria of PSP [8]. O: Ocular motor dysfunction; P: Postural instability; A: Akinesia; C: Cognitive dysfunction; PSP-RS: PSP with Richardson’s syndrome; PSP-P: PSP with predominant parkinsonism; PSP-PGF: PSP with progressive gait freezing; PSP-F: PSP with predominant frontal presentation; PSP-PI: PSP with predominant postural instability; PSP-SL: PSP with predominant speech/language disorder; PSP-OM: PSP with predominant ocular motor dysfunction.

EMR-VOG results

Saccades characteristics from VOG recording are summarized in Table 2.

It is important to underline the importance of oculomotor quantitative VOG measures at PSP onset that could show subtle changes in saccades parameters whereas bed side testing could be considered as normal (Table 2).

PSP subtype	Latency	V mean (°/sec)	V max (°/sec)	Gain	Antisaccade errors rate
Horizontal saccades					
s.o. PSP-OM	187.2 (34.2)	65.43	135.51	0.60 (0.12)	0.75 (0.18)
s.o. PSP-P	251.68 (100.54)	223.05 (58.93)	415.97 (95.34)	0.82 (0.14)	0.79 (0.16)
poss. PSP-PGF	285.28 (135.54)	262.31 (81.60)	479.18 (135.91)	0.85 (0.08)	0.78 (0.31)
s.o. PSP-PI	216.29 (67.86)	140.56 (96.81)	260.02 (162.99)	0.92 (0.63)	0.68 (0.21)
s.o. PSP-SL	186.6 (26.32)	140.56 (56.81)	260.02 (42.52)	0.73 (0.19)	0.8 (0.15)
All patients	237.46 (87.62)	226.03 (81.04)	425.97 (135.07)	0.85 (0.38)	0.76 (0.18)
Vertical saccades					
s.o. PSP-OM	359.37 (35.23)	46.78 (21.51)	86.985 (42.65)	0.32 (0.18)	
s.o. PSP-P	313.70 (65.08)	137.58 (63.40)	274.32 (102.33)	0.71 (0.16)	
poss. PSP-PGF	274.95 (45.02)	161.20 (16.04)	339.54 (70.87)	0.87 (0.25)	
s.o. PSP-PI	311.58 (78.10)	127.94 (73.35)	266.57 (140.52)	0.77 (0.13)	
s.o. PSP-SL	611.01 (36.15)	133.99 (35.23)	226.67 (55.42)	0.81 (0.14)	
All patients	320.21 (80.62)	133.07 (62.12)	270.87 (111.96)	0.76 (0.17)	

Table.2 Baseline saccades' characteristics (VOG) according to PSP subtypes, mean (SD). s.o (suggestive), p (possible), PSP-OM: PSP with predominant ocular motor dysfunction, PSP-SL: PSP with predominant speech/language disorders, PSP-PGF: PSP with progressive gait freezing, PSP-P: PSP with predominant parkinsonism, PSP-PI: PSP with predominant postural instability.

FDG-PET analysis (Fig.2)

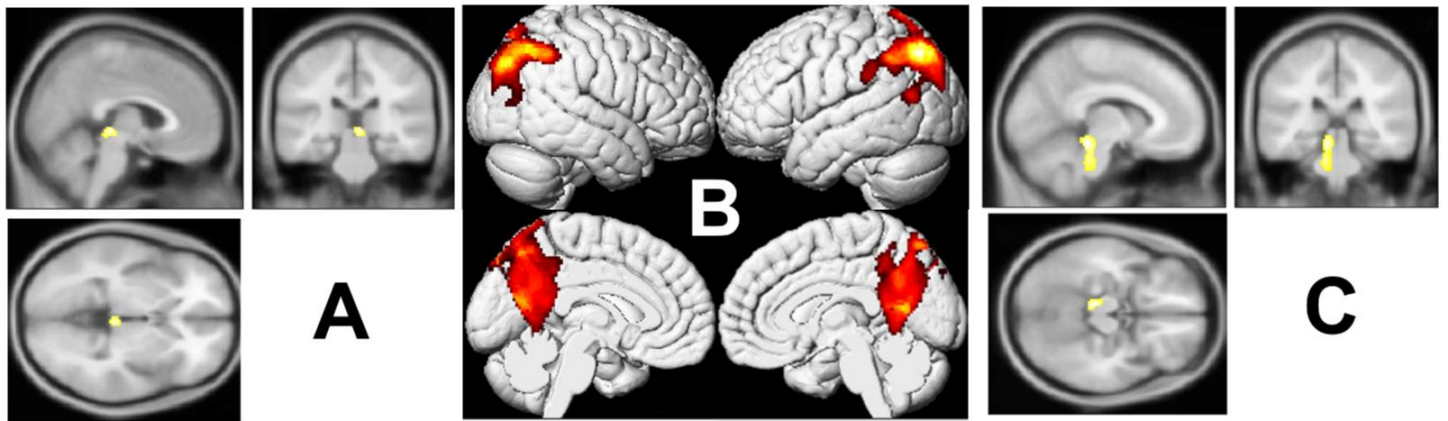


Fig.2 Brain 18FDG-PET correlates between metabolism and oculomotricity features (A and C: p-voxel < 0.005, uncorrected, p-cluster < 0.05, FWE-corrected, using a sphere of 12mm-radius; B: p-voxel < 0.001, uncorrected, p-cluster < 0.05, FWE-corrected) A: *Vertical saccades gain is positively correlated to the metabolism of the right superior colliculus* B: *Horizontal saccades latency is negatively correlated to bilateral metabolism in posterior parietal cortex and precuneus with an extension to the occipital cortex* C: *Average velocity of the horizontal saccades is positively correlated to the metabolism of the left SC and dorsal nuclei in pons*

Vertical gaze

Vertical saccade gain was positively correlated with metabolism of the right superior colliculus (SC) (T-score max = 3.62; p-voxel = 0.027 FWE-corrected and p-cluster = 0.05 FWE-corrected using small volume correction by a sphere of 12mm-radius; k = 75; peak MNI coordinates: 4 -28 -2).

Horizontal gaze

We found a negative correlation between horizontal saccades latency and bilateral metabolism in posterior parietal cortex (PPC) and precuneus with an extension to the occipital cortex (T-score max = 7.91; p-voxel = 0.001 FWE-corrected, p-cluster < 0.001 FWE-corrected using a whole-brain analysis; k = 9,520; peak MNI coordinates: -46 -70 48)

We additionally found a positive correlation between average velocity of the horizontal saccades and the left superior colliculus and also dorsal nuclei in the pons (T-score max = 4.06; p-voxel = 0.010 FWE-corrected and p-cluster = 0.024 FWE-corrected using small volume correction by a sphere of 12mm-radius; k = 188; peak MNI coordinates: -8 -32 -16) ,

Antisaccades

We found no correlation between antisaccades EMR-VOG-features and cerebral metabolism.

Discussion

The present study aimed to explore the brain metabolic correlates of oculomotor features from EMR-VOG records of PSP patients at an early stage of disease. Longitudinal follow-up enabled diagnosis confirmation according to PSP-MDS criteria. We found that reduced glucose metabolism in SC was associated with reduced vertical saccade gain. Furthermore, reduction of glucose metabolism in SC and dorsal nuclei in the pons were also associated with slowness of horizontal saccades. Finally, increase of saccade latency correlated with decrease of glucose metabolism in PPC.

To our knowledge, this is the first study investigating regional functional correlates of oculomotor disorders at early course of PSP. In a previous study focusing on the same objective, Amtage et al. correlated oculomotor records and PET imaging data at the stage of probable PSP for most patients. Patients in our study were included earlier in the course of disease (stage of possible PSP) even before any clinically observable ocular symptoms onset except in one patient. Moreover, our study included a slightly larger sample of patients than Amtage et al. 's [11]. Finally, we also performed a longitudinal follow-up of participants that strengthened the diagnosis of PSP.

Several pathological and neuroimaging studies emphasized relationship between vertical gaze palsy and midbrain atrophy [2,13]. However, functional brain correlates of saccades parameters have received little attention [14]. Amtage et al. [11] found no correlation between vertical gaze palsy and brainstem activity. We found a significant correlation between vertical saccade gain and SC activity and no significant correlation between vertical saccade velocity and brainstem activity. It has been suggested that excitatory burst neurons (EBNs) in riMLF rather than omnipause neurons (OPN) in pons are responsible of selective impairment of vertical saccades early in the course of the disease [15]. However, a recent study demonstrated that slow eye movements in PSP are not the exclusive consequence of decreased saccadic velocity but are also caused by curved and irregular trajectory and interruptions in ongoing saccade, especially at early stages of disease [7]. Referring to previous electrophysiological studies on primates in which a selective stimulation of the fixation zone of the SC resulted in interrupted and curved saccades trajectories, the authors obtained similar results in saccadic records in PSP patients. Therefore, the maladaptive firing in SC activity might lead to several alterations in saccade trajectory and, particularly, saccades interruptions. Consequently, a decrease in saccade gain does not necessary reflect the saccade hypometria but rather the series of subsequent eye movements to bring the gaze toward the target. Several interruptions in ongoing saccade result in a curved shape of the trajectory suggesting "round-the-house" sign on eye movement records and

could be related to abnormal function of the pontine- mesencephalic saccade generation network and a subsequent maladaptive process at the level of SC, which could be evidenced early in the course of PSP [7].

In primates, the ventral layers of SC are more pertinent for the control of eye movements and contain a motor map that predicts the size and direction of saccades [16]. Lesion of the SC abolishes express saccades whereas discrete experimental lesions of the SC in monkeys cause enduring deficit in prosaccades, with increased slowness [17]. Hence, these data are consistent with the results of our study in which a significant correlation between mean velocity of horizontal prosaccades and FDG-PET activity of SC was found. Other studies found similar results in patient with advanced PD, showing that hypometric, slow and maladaptive saccades are associated with SC abnormalities [18]. Indeed in advanced PD, gaze shift can only be achieved by a series of small saccades on eye movements record, giving the appearance of a staircase of saccades to orient the eye to its target, closely similar to the “round-the house” sign reported in PSP [19].

Our results also showed a correlation between mean velocity of horizontal saccades and brain metabolism in dorsal nuclei in the pons that are critical components of the premotor commands for saccades. For horizontal saccades, EBNs within the paramedian pontine reticular formation (PPRF) are essential in creating the immediate premotor command that generate the pulse of activity [20]. The inhibitory function of OPN that lies in the Nucleus Raphe Interpositus (RIP) in the midline of the pons is finely tuned through many projections that arise from SC but also cortical and other brain stem areas[21,22]. By acting as an inhibitory switch, OPN help maintaining the necessary synchronization of the activity of saccadic burst neurons to drive the eyes rapidly during the saccade and to keep the eyes still when the saccade is over[23].

Our results demonstrate that latency of horizontal saccades increases together with a decreased activity in the PPC. The parietal eyed field (PEF) is a particular subregion of the PPC involved in saccadic control. It sends projections to the SC to achieve a visuomotor transformation of the signal. This pathway has an important role in express saccades (gap-paradigm) and may be the structure that triggers them [24]. The increase of saccadic latency is due to defective ability to disengage, shift and reengage visual attention in relation with activity of fronto-parietal brain areas. Indeed, the PPC plays a key role in visual attention shifting, which may be accompanied by saccades [25]. The PEF is directly involved in programming saccades to visual targets based on a hypothetical priority (interest, attention) map of external space. Lesions involving the PEF in human cause prolonged latency of visually guided saccades during gap and overlap paradigms [26]. These findings suggest that early alterations of saccadic control in PSP could be related to activity changes in direct projections of parietal cortex to SC. This pathway is involved in reorienting gaze to novel visual stimuli, in particular

in shifting visual attention to the location of new targets appearing in our visual world. These findings could also provide a theoretical frame to account for several behavioral abnormalities observed in PSP such as dependence to environmental stimuli, a form of “gaze grasping”, interpreted as the impossibility of PSP patients to disengage their visual attention from salient visual stimuli of the environment (environment-generated gaze) [27]. Alternatively, they could also to be the consequence of released parietal lobe behaviors from inhibitory inputs arising from dorsal prefrontal cortex and basal ganglia circuits [27]. Pathways arising from prefrontal areas (Frontal Eye Field, Supplementary Eye Field, dorsolateral prefrontal cortex) and projecting to SC, directly or indirectly via basal ganglia, appear more concerned with the preparation for self-generated changes in gaze as a part of remembered, anticipated, or learned behavior. Taken together, our results highlight the role of SC as an important brainstem target of the saccade-related cortical eye field. It is a pivotal structure, integrating and relaying commands from the cerebral cortex onto premotor brainstem saccadic pulse generators by inhibitory and excitatory influences. We summarized those elements in **Fig.3**. The apparent asymmetry of correlation findings between right and left SC for vertical and horizontal saccades might results from heterogeneous nature of the patients group presenting with various clinical features suggestive of PSP, in particular some of them having asymmetric onset (see table 1). We can also highlight the restrictive threshold used for correlations analysis, which could underestimate involvement of contralateral SC for each type of saccades.

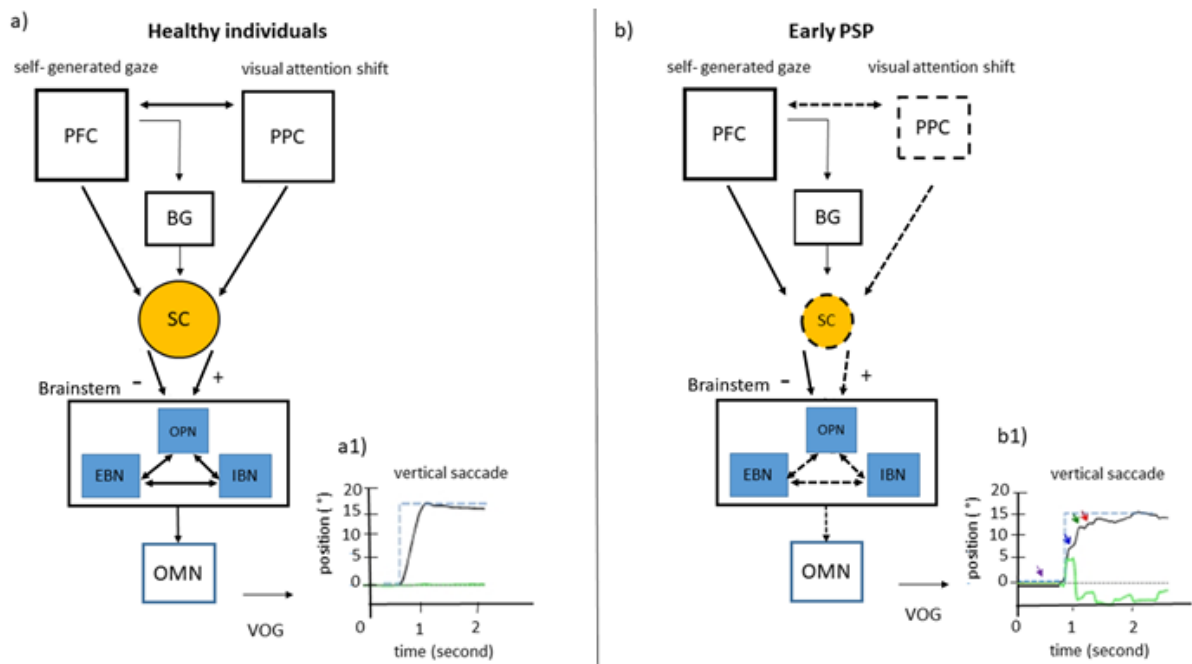


Fig.3 Saccade network in healthy individuals and possible impairments in early PSP. Video oculography (VOG) records. Eye position is plotted on the y-axis, and the x-axis depicts the corresponding time in

seconds. Blacklines indicate the vertical eye position; green traces illustrate the horizontal eye position, gray dashed lines depict the baseline straight-ahead position, blue dashed lines depict the position of the target (desired eye position). (a) In healthy individuals, inputs from posterior parietal cortex (PPC) and prefrontal cortex (PFC) via direct or indirect pathways through basal ganglia are sent to superior colliculus (SC). SC is a pivotal structure, integrating and relaying commands from the cerebral cortex onto premotor brainstem saccadic pulse generator by inhibitory and excitatory influences. Two types of neurons are critical components of saccade-generating pontine –mesencephalic circuits: burst neurons (inhibitory (IBN) and excitatory (EBN)) and omnipause neurons (OPN) that forward the command to the final oculomotor pathway represented by oculomotor nuclei (OMN). (a1) VOG record of the normal vertical saccade trajectory. (b) In early PSP, impairments in SC might lead to maladaptive inhibitory and excitatory inputs to brainstem saccade generators. Supplementary alterations of interconnections between frontal and posterior parietal lobe, could induce activity changes in direct projections from PPC cortex to SC and consequently early impairments of saccadic control. (b1) VOG record of several interruptions (blue, red, and green arrows) in ongoing saccade resulting in a curved shape of the saccade trajectory suggesting “round-the- house» sign. The initiation of saccade is often abnormal with variable latencies (purple arrow)

In our study, we found no correlation between errors in antisaccades task and the frontal cortex metabolism. A meta-analysis of imaging studies in normal subjects showed that antisaccades are preferentially associated with widespread activation in frontal and parietal regions, striatum, thalamus and cerebellar areas (regions associated with saccade generation as well), but not in the superior colliculus, substantia nigra and globus pallidus [28,29]. Abnormalities in antisaccades tasks are usually evidenced in patients with frontal lobe lesions, but also with parietal lobes lesions and post traumatic conditions, psychiatric disorders, and even in normal subjects with certain personality traits or special talents [30]. In spite of growing neuroimaging data, the precise role of these different structures in generating saccades and suppressing prosaccades in antisaccades task, and in the temporal cascade of decision making, are not well established. Therefore, the absence of specific correlates between errors in antisaccades and regional brain metabolism observed in this study could be explained by the nature of the antisaccades task itself, which involves a complex chain of processes and brain structures (including basal ganglia), none of them achieving the significant correlation threshold when studied in PSP patients at early stage of the disease.

This work has several limitations. First, all data were retrospectively collected from a patient’s population issued from routine clinical practice. In consequence, no control subjects’ data or longitudinal VOG and brain metabolic measures was available for comparison. The overall design of our study was similar to that of Amtage and colleagues one’s except that the PSP patients included here were at an earlier stage of the disease [11]. While patients were diagnosed in two tertiary centers

and records were carefully examined by experienced neurologists, our study lacked autopsy-confirmed cases and the risk of false positive diagnosis cannot fully be ruled out.

In conclusion, we found several correlations between EMR-VOG and FDG-PET at early stage of PSP. The most striking finding in our study is the involvements of SC in several saccadic abnormalities early in the course of the disease, especially in saccadic gain and velocity. These data support the role of SC in oculomotor saccadic functions as an important plug in the saccadic neural network [27, 28] and its early involvement in the pathogenesis of oculomotor disorders in PSP. Moreover, these results can contribute to the development of prodromal disease biomarkers and help providing reliable measures of disease progression for the purpose of clinical follow-up or putative pharmacological trials. Further studies with a prospective longitudinal design and inclusion of a control subjects' group for VOG and FDG uptake measures comparisons, are needed to confirm these findings.

Author's roles

G. Pin: Reviewing and editing

J. Labouré: Conceptualization, data curation, formal analysis, writing original draft, visualization

E. Guedj: Conceptualization, data curation, formal analysis, writing original draft, supervision

O. Felician: reviewing and editing

S. Grimaldi: reviewing and editing

JP. Azulay: reviewing and editing

M. Ceccaldi: reviewing and editing

L. Koric: Conceptualization, data curation, formal analysis, writing original draft, visualization, supervision

Disclosures

Authors have no financial interest or relationships to disclose.

All authors have approved the final article.

Bibliography

- 1 Litvan I, Agid Y, Calne D, *et al.* Clinical research criteria for the diagnosis of progressive supranuclear palsy (Steele-Richardson-Olszewski syndrome): Report of the NINDS-SPSP International Workshop*. *Neurology* 1996;**47**:1–9. doi:10.1212/WNL.47.1.1
- 2 Steele JC, Richardson JC, Olszewski J. PROGRESSIVE SUPRANUCLEAR PALSY. A HETEROGENEOUS DEGENERATION INVOLVING THE BRAIN STEM, BASAL GANGLIA AND CEREBELLUM WITH VERTICAL GAZE AND PSEUDOBULBAR PALSY, NUCHAL DYSTONIA AND DEMENTIA. *Arch Neurol* 1964;**10**:333–59. doi:10.1001/archneur.1964.00460160003001
- 3 Respondek G, Kurz C, Arzberger T, *et al.* Which ante mortem clinical features predict progressive supranuclear palsy pathology? *Mov Disord* 2017;**32**:995–1005. doi:10.1002/mds.27034
- 4 Respondek G, Stamelou M, Kurz C, *et al.* The phenotypic spectrum of progressive supranuclear palsy: a retrospective multicenter study of 100 definite cases. *Mov Disord* 2014;**29**:1758–66. doi:10.1002/mds.26054
- 5 Höglinger GU, Respondek G, Stamelou M, *et al.* Clinical diagnosis of progressive supranuclear palsy: The movement disorder society criteria: MDS Clinical Diagnostic Criteria for PSP. *Movement Disorders* 2017;**32**:853–64. doi:10.1002/mds.26987
- 6 Marx S, Respondek G, Stamelou M, *et al.* Validation of mobile eye-tracking as novel and efficient means for differentiating progressive supranuclear palsy from Parkinson's disease. *Frontiers in Behavioral Neuroscience* 2012;**6**. doi:10.3389/fnbeh.2012.00088
- 7 Shaikh AG, Factor SA, Juncos JL. Saccades in Progressive Supranuclear Palsy-Maladapted, Irregular, Curved, and Slow. *Movement Disorders Clinical Practice* 2017;**4**:671–81. doi:10.1002/mdc3.12491
- 8 Rivaud-Pechoux S, Vidailhet M, Gallouedec G, *et al.* Longitudinal ocular motor study in corticobasal degeneration and progressive supranuclear palsy. *Neurology* 2000;**54**:1029–32. doi:10.1212/WNL.54.5.1029
- 9 Garbutt S. Saccade Abnormalities in Autopsy-Confirmed Frontotemporal Lobar Degeneration and Alzheimer Disease. *Arch Neurol* 2012;**69**:509. doi:10.1001/archneurol.2011.1021
- 10 Groschel K, Kastrup A, Litvan I, *et al.* Penguins and hummingbirds: Midbrain atrophy in progressive supranuclear palsy. *Neurology* 2006;**66**:949–50. doi:10.1212/01.wnl.0000203342.77115.bf
- 11 Amtage F, Maurer C, Hellwig S, *et al.* Functional correlates of vertical gaze palsy and other ocular motor deficits in PSP: An FDG-PET study. *Parkinsonism & Related Disorders* 2014;**20**:898–906. doi:10.1016/j.parkreldis.2014.05.013
- 12 Verger A, Grimaldi S, Ribeiro M, *et al.* Single Photon Emission Computed Tomography/Positron Emission Tomography Molecular Imaging for Parkinsonism: A Fast-Developing Field. *Ann Neurol* 2021;**90**:711–9. doi:10.1002/ana.26187
- 13 Buch KA, Bouffard MA, Kardon RH, *et al.* Clinical Correlation Between Vertical Gaze Palsy and Midbrain Volume in Progressive Supranuclear Palsy. *J Neuroophthalmol* 2022;**42**:246–50. doi:10.1097/WNO.0000000000001393
- 14 Jaillard A, Petyt G, Morelle M. [18F]-Fdg Pet Identified Superior Colliculi Hypometabolism in Progressive Supranuclear Palsy. *J Alzheimers Dis Parkinsonism* 2016;**06**. doi:10.4172/2161-0460.1000278

- 15 Bhidayasiri R, Riley DE, Somers JT, *et al.* Pathophysiology of slow vertical saccades in progressive supranuclear palsy. *Neurology* 2001;**57**:2070–7. doi:10.1212/wnl.57.11.2070
- 16 Soetedjo R, Kaneko CRS, Fuchs AF. Evidence That the Superior Colliculus Participates in the Feedback Control of Saccadic Eye Movements. *Journal of Neurophysiology* 2002;**87**:679–95. doi:10.1152/jn.00886.2000
- 17 Hanes DP, Smith MK, Optican LM, *et al.* Recovery of saccadic dysmetria following localized lesions in monkey superior colliculus. *Exp Brain Res* 2005;**160**:312–25. doi:10.1007/s00221-004-2013-z
- 18 Terao Y, Fukuda H, Ugawa Y, *et al.* New perspectives on the pathophysiology of Parkinson’s disease as assessed by saccade performance: A clinical review. *Clinical Neurophysiology* 2013;**124**:1491–506. doi:10.1016/j.clinph.2013.01.021
- 19 Blekher T, Weaver M, Rupp J, *et al.* Multiple step pattern as a biomarker in Parkinson disease. *Parkinsonism & Related Disorders* 2009;**15**:506–10. doi:10.1016/j.parkreldis.2009.01.002
- 20 Horn AKE. The reticular formation. *Prog Brain Res* 2006;**151**:127–55. doi:10.1016/S0079-6123(05)51005-7
- 21 Büttner-Ennever JA, Horn AK, Henn V, *et al.* Projections from the superior colliculus motor map to omnipause neurons in monkey. *J Comp Neurol* 1999;**413**:55–67. doi:10.1002/(sici)1096-9861(19991011)413:1<55::aid-cne3>3.0.co;2-k
- 22 Stanton GB, Goldberg ME, Bruce CJ. Frontal eye field efferents in the macaque monkey: II. Topography of terminal fields in midbrain and pons. *J Comp Neurol* 1988;**271**:493–506. doi:10.1002/cne.902710403
- 23 Shinoda Y, Sugiuchi Y, Takahashi M, *et al.* Neural substrate for suppression of omnipause neurons at the onset of saccades: Shinoda *et al.* *Annals of the New York Academy of Sciences* 2011;**1233**:100–6. doi:10.1111/j.1749-6632.2011.06171.x
- 24 Sparks D, Rohrer WH, Zhang Y. The role of the superior colliculus in saccade initiation: a study of express saccades and the gap effect. *Vision Res* 2000;**40**:2763–77. doi:10.1016/s0042-6989(00)00133-4
- 25 Bisley JW, Goldberg ME. Attention, Intention, and Priority in the Parietal Lobe. *Annu Rev Neurosci* 2010;**33**:1–21. doi:10.1146/annurev-neuro-060909-152823
- 26 Pierrot-Deseilligny C, Rosa A, Masmoudi K, *et al.* Saccade deficits after a unilateral lesion affecting the superior colliculus. *Journal of Neurology, Neurosurgery & Psychiatry* 1991;**54**:1106–9. doi:10.1136/jnnp.54.12.1106
- 27 Ghika J, Tennis M, Growdon J, *et al.* Environment-driven responses in progressive supranuclear palsy. *Journal of the Neurological Sciences* 1995;**130**:104–11. doi:10.1016/0022-510X(95)00015-T
- 28 Shires J, Joshi S, Basso MA. Shedding new light on the role of the basal ganglia-superior colliculus pathway in eye movements. *Current Opinion in Neurobiology* 2010;**20**:717–25. doi:10.1016/j.conb.2010.08.008
- 29 Jamadar SD, Fielding J, Egan GF. Quantitative meta-analysis of fMRI and PET studies reveals consistent activation in fronto-striatal-parietal regions and cerebellum during antisaccades and prosaccades. *Front Psychol* 2013;**4**. doi:10.3389/fpsyg.2013.00749
- 30 Kang SS, Dionisio DP, Sponheim SR. Abnormal mechanisms of antisaccade generation in schizophrenia patients and unaffected biological relatives of schizophrenia patients. *Psychophysiology*

2011;48:350–61. doi:10.1111/j.1469-8986.2010.01074.x