



HAL
open science

Ethanol endometrioma sclerotherapy: safety through 8 years of experience

L Miquel, J Liotta, A Pivano, A Gnisci, A Netter, B Courbiere, A Agostini

► **To cite this version:**

L Miquel, J Liotta, A Pivano, A Gnisci, A Netter, et al.. Ethanol endometrioma sclerotherapy: safety through 8 years of experience. *Human Reproduction*, 2024, 39 (4), pp.733-741. 10.1093/hum-rep/deae014 . hal-04495557

HAL Id: hal-04495557

<https://amu.hal.science/hal-04495557v1>

Submitted on 16 Jan 2025

HAL is a multi-disciplinary open access archive for the deposit and dissemination of scientific research documents, whether they are published or not. The documents may come from teaching and research institutions in France or abroad, or from public or private research centers.

L'archive ouverte pluridisciplinaire **HAL**, est destinée au dépôt et à la diffusion de documents scientifiques de niveau recherche, publiés ou non, émanant des établissements d'enseignement et de recherche français ou étrangers, des laboratoires publics ou privés.

Ethanol endometrioma sclerotherapy: safety through 8 years of experience

L. Miquel^{1,*†}, J. Liotta^{1,†}, A. Pivano¹, A. Gnisci¹, A. Netter^{1,2}, B. Courbiere^{1,2}, and A. Agostini¹

¹Department of Obstetrics Gynecology and Reproductive Medicine, Pôle femmes parents enfants, La Conception University Hospital, Marseille, France

²Department of Mediterranean Institute of marine and terrestrial Biodiversity and Ecology, Aix Marseille Univ, Avignon Université, CNRS, IRD, IMBE, Marseille, France

ABSTRACT

STUDY QUESTION: What are the complications of transvaginal ethanol sclerotherapy for the treatment of endometriomas?

SUMMARY ANSWER: Sclerotherapy is a reliable, minimally invasive method applicable in outpatient procedures but with specific and potential life-threatening complications that need to be identified and prevented.

WHAT IS KNOWN ALREADY: There are currently few data on the use of transvaginal ethanol sclerotherapy, and we mainly note septic complications.

STUDY DESIGN, SIZE, DURATION: A retrospective observational cohort study was carried out. The study was conducted at an academic hospital and included 126 women aged 31.9 ± 5.5 years (mean \pm SD), between November 2013 and June 2021. We analyzed a total of 157 ethanol sclerotherapy treatment (EST), treated by 131 EST procedures, in 126 women.

PARTICIPANTS/MATERIALS, SETTING, METHODS: The study included women with an indication for transvaginal ethanol sclerotherapy. Indications were women with at least one endometrioma over 10 mm, isolated or associated with other endometriosis locations, requiring treatment for pain or infertility before assisted reproductive treatment. We followed a standardized transvaginal ethanol sclerotherapy procedure consisting of an ultrasound-guided transvaginal puncture of one or more endometriomas under general anesthesia. The cyst content was completely removed and flushed with saline solution. Ethanol (96%) was injected at 60% of the initial volume of the endometrioma, remained in the cyst for 10 min and was then completely removed. Ethanol loss was defined as a loss of 5 ml or more than 10% of the initial volume of the injected ethanol. Failure was defined by the contraindication of endometrioma puncture because of interposition of the digestive tract, ethanol loss in the previous endometrioma treated (in case of multiple ESTs), failure to aspirate the endometriotic fluid, contraindication to start ethanol injection owing to saline solution leakage, or contraindication to continue ethanol injection owing to suspicions of ethanol leakage at sonography. Intraoperative complications were defined by ethanol loss, positive blood alcohol level, and ethanol intoxication. Postoperative complications were defined by fever, biological inflammatory syndrome, and ovarian abscess. Complications were classified according to the Clavien and Dindo surgical classification, which is a system for classifying postoperative complications in five grades of increasing severity.

MAIN RESULTS AND THE ROLE OF CHANCE: We reported a total of 17/157 (10.8%) transvaginal ethanol sclerotherapy failures during 14/131 (10.7%) transvaginal ethanol sclerotherapy procedures in 13/126 (10.3%) women. In the same sets of data, complication was reported for 15/157 (9.5%) transvaginal ethanol sclerotherapy in 13/131 (9.9%) transvaginal ethanol sclerotherapy procedures in 13/126 (10.3%) women. Nine of 126 women (7.1%) had a grade I complication, one (0.8%) had a grade II complication (medical treatment for suspicion of pelvic infection), two (1.6%) had a grade III complication (ovarian abscess) and one (0.8%) had a grade IV complication (ethanol intoxication). We did not observe any grade V complications.

LIMITATIONS, REASONS FOR CAUTION: This was a retrospective study and pain assessment not considered. The benefit-risk balance of endometrioma transvaginal ethanol sclerotherapy was not evaluated.

WIDER IMPLICATIONS OF THE FINDINGS: Our study is the first to evaluate the complications of transvaginal ethanol sclerotherapy with such a large cohort of women in a standardized protocol. Transvaginal ethanol sclerotherapy seems to be an effective alternative to laparoscopic surgery in the management of endometriomas and limits the alteration of ovarian reserve. Transvaginal ethanol sclerotherapy is a reliable, minimally invasive method applicable on an outpatient basis. The majority of complications are Clavien–Dindo \leq IV, for which preventative measures, or at least early diagnosis and treatment, can be easily performed. The risk of ethanol intoxication is rare, but it is a life-threatening risk that must be avoided by appropriate implementation and promotion of the sclerotherapy procedures.

STUDY FUNDING/COMPETING INTEREST(S): None.

TRIAL REGISTRATION NUMBER: Aix Marseille University's ethics committee registration number 2021-06-03-01.

Keywords: sclerotherapy / endometriosis / endometrioma / complication / ethanol / ultrasound / fertility / mini-invasive surgery / infection / alcohol intoxication

Introduction

Endometriosis is a common pathology, affecting about 10% of women worldwide (Eskenazi and Warner, 1997). Endometriomas are detected in up to 44% of women with endometriosis (Chapron et al., 2002) and are associated with pelvic pain, deep lesions, and disease severity (Chapron et al., 2019). Owing to their involvement in the alteration of women's quality of life, treating endometriomas with minimally invasive techniques remains a challenge. Currently, conventional laparoscopic surgery with divergent cystectomy traction is still the standard treatment (Nezhat et al., 1989; Vercellini et al., 2006; Hart et al., 2008). This technique has been shown to increase the natural pregnancy rate in infertile women and treat pain in symptomatic women (Hart et al., 2008). However, evidence suggests that the ovarian reserve is compromised during the surgical excision of endometriomas, especially in the case of multiple interventions (Garcia-Velasco and Somigliana, 2009; Roustan et al., 2015). Transvaginal ethanol sclerotherapy treatment (EST) under ultrasound guidance for endometrioma was first described in 1988 in Japan by Akamatsu et al. (1988). Yazbeck et al. (2009, 2012) later standardized the current technique commonly used (Miquel et al., 2021). Several agents have been used to induce direct destruction of the cyst wall (tetracycline, methotrexate, and ethanol), but ethanol is currently the most evaluated and used (Aboulghar et al., 1993; Agostini et al., 2007; Hsieh et al., 2009; Shawki et al., 2011; Wang et al., 2015; Cohen et al., 2017). However, the preoperative and postoperative complications of transvaginal EST for endometrioma are poorly reported. The aim of this study is to report and describe the failures and complications of transvaginal EST.

Materials and methods

This was a retrospective cohort study conducted in a French academic center (La Conception Hospital, Marseille, France) between November 2013 and June 2021. Aix Marseille University's ethics committee approved the study in June 2021 (2021-06-03-01).

The inclusion criteria were women with an indication of EST, over 18 years old, and affiliated with the French healthcare system. All women gave written informed consent to provide their medical data to be used in this study.

During this period, the indications of EST were women presenting with at least one endometrioma with a diameter over 10 mm, isolated or associated with other endometriosis locations, and requiring specific treatment for pain or infertility before undergoing ART. Endometriomas could be primary or recurrent.

All women had MRI before EST to minimize the risk of misdiagnosing a malignant cyst and to specify the diagnosis of endometrioma. As EST is not the standard treatment, indications were discussed during multidisciplinary endometriosis meetings, and appropriate information was given to all the women. For women requiring treatment of endometrioma and other locations of endometriosis, EST was associated with the surgical treatment of endometriosis by laparoscopy. EST was performed first, followed by laparoscopy for deep endometriosis treatment during the same intervention.

The recorded variables were demographic and clinical data, endometrioma size before and after EST, initial cyst volume, ethanol volume injected, ethanol volume removed, length of EST, blood alcohol level after EST, intraoperative complications (e.g. organs injury and blood transfusion), and postoperative complications in the month following EST according to the Clavien-Dindo classification (Dindo et al., 2004).

Est protocol

Routinely, we followed the standardized EST technique, as previously described by Yazbeck et al. (2009), which consists of an ultrasound-guided transvaginal puncture of one or more endometriomas (Miquel et al., 2021). The intervention was performed by a trained gynecologist in the outpatient department in a lithotomy position under general anesthesia. All women presented with a negative vaginal swab 1 week before the procedure. Antibiotic prophylaxis with 2 g Cefazolin was systematically administered during EST to prevent pelvic infection. The initial position and size of the endometrioma were recorded (Fig. 1a). The endometrioma was transvaginally punctured under ultrasound guidance using a single lumen 17 G × 250 mm needle (Fig. 1b). EST was not performed if interposition of the digestive tract was identified. The cyst content was completely removed, and its volume was measured. Part of the liquid was sent to cytology for analysis. Immediately after the complete cyst content removal was confirmed by sonography, the cyst was flushed with saline solution until a clear liquid was obtained. Then, 96% ethanol was injected at 60% of the initial volume of the endometrioma to not over-distend and to avoid any rupture of the cyst and ethanol diffusion into the pelvis (Fig. 1c). Ethanol was not injected if leakage of saline solution, indicating cyst rupture, was diagnosed by sonography during flushing (saline solution leakage). The ethanol injection was stopped if a leak was detected during the injection by sonography (ethanol leakage). Ethanol remained in the cyst for 10 min and was then completely removed (Fig. 1d). The recovered volume was noted. Ethanol loss was defined as a loss of more than 10% of the initial volume of injected ethanol. Beyond 5 ml of ethanol loss, we considered that there was an ethanol loss, whatever the volume of ethanol initially injected. In this case, we recommended that each woman's blood alcohol level be monitored, and the anesthetic team was notified. If the blood alcohol level was positive, the woman was more closely monitored. All patients were warned of the possibility of a positive blood alcohol level. They were forbidden to drive for 12 h following their procedure.

We defined the EST procedure as single, double, or triple according to the number of ESTs performed during the same procedure.

EST failure was defined by the contraindication of endometrioma puncture because of interposition of the digestive tract, ethanol loss in the previous endometrioma treated in case of multiple ESTs, failure to aspirate the endometriotic fluid as it is too thick and contains solid clotted parts, contraindication to start ethanol injection owing to saline solution leakage, or contraindication to continue ethanol injection owing to suspicions of ethanol leakage at sonography.

In case of multiple ESTs, the procedure was stopped if a failure or intraoperative complication happened on the first or second endometrioma treated. Therefore, untreated endometriomas were considered EST failures.

In case of EST failure, a laparoscopic cystectomy was planned or not, according to the preoperative information and alternatives suggested to the woman before the EST procedure.

Intraoperative complications were defined as ethanol loss, positive blood alcohol level, and ethanol intoxication.

Postoperative complications were defined as fever, biological inflammatory syndrome, and ovarian abscess.

Complications were classified according to the Clavien and Dindo surgical classification, which is a system for classifying post-operative complications in five grades of increasing severity (Dindo et al., 2004).

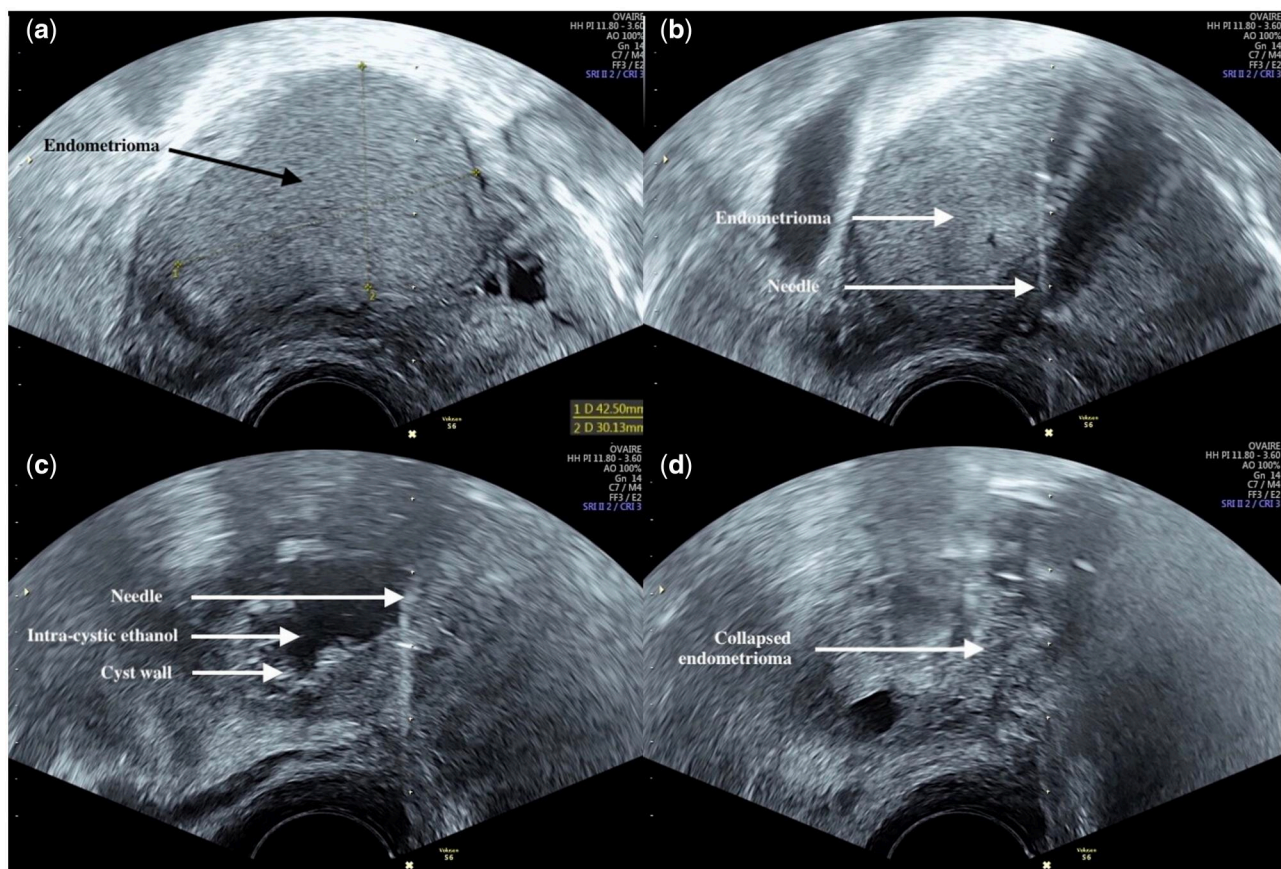


Figure 1. Transvaginal ethanol sclerotherapy treatment protocol in women. (a) Initial position and size of the endometrioma. (b) Transvaginal endometrioma puncture under ultrasound guidance. (c) 96% ethanol injection at 60% of the initial volume of the endometrioma. (d) Final aspect.

The characteristics of the women were also collected. Some women had recurrent endometrioma initially treated with an EST procedure and then required a second EST procedure (two procedures). Some women had several endometriomas treated by EST in the same EST procedure (single, double, or triple EST procedure). Each endometrioma treated by EST was considered as one EST. Thus, some women may have more than one EST because of a recurrent endometrioma or several endometriomas on one or both ovaries treated at the same time. The term 'EST' refers to the treatment of an endometrioma by ethanol sclerotherapy, the term 'EST procedure' refers to the intervention period when one or more endometriomas could be treated, while the term 'women' refers to woman treated. Women were followed as outpatients for the those requiring simple EST or as conventional inpatients for the women who underwent EST and laparoscopic surgery for associated endometriosis. A visit to the hospital was scheduled for 1 month later.

Results

Between November 2013 and October 2021, 126 women underwent at least one EST procedure for pain treatment (68/126 (54.0%)) or infertility (58/126 (46.0%)). All the infertile women underwent IVF after EST to treat infertility. The women's characteristics are reported in [Table 1](#).

Ninety-seven of 126 (77.0%) women underwent an exclusive EST procedure, while 29/126 (23.0%) women were treated in a combined procedure with surgery for deep endometriosis.

Among these 126 women, five (4.0%) underwent the EST procedure twice. One woman underwent a second EST procedure

because the first EST procedure failed. Four women underwent a second EST procedure for recurrent endometrioma. All four presented with a new endometrioma after the first EST procedure for a unique endometrioma. For three of the women, recurrence occurred in the contralateral ovary between 8 and 18 months after the first EST procedure; for one woman, recurrence occurred in the same ovaria 41 months after the first EST procedure.

We analyzed a total of 157 EST treated by 131 EST procedures in 126 women.

One EST was performed in 108 EST procedures, two in 20 EST procedures, and three in three EST procedures. Among these 126 women, the data for 37 women have been published in a previous study ([Miquel et al., 2020](#)).

The characteristics of the endometriomas are presented in [Table 2](#). We performed seven EST under 30 mm. All EST procedures under 30 mm were performed on endometrioma resistant to medical treatment in women without a desire for conventional cystectomy. We treated endometriomas from 10 mm up to 140 mm and injected ethanol in volumes from 1 ml up to 540 ml.

Failures

We reported a total of 17/157 (10.8%) EST failures during 14/131 (10.7%) EST procedures in 13/126 (10.3%) women. Among these 14 EST procedures, we found two contraindications of puncture because of interposition of the digestive tract (single EST), two failures to aspirate the endometriotic fluid as it was too thick and contained solid clotted parts (single EST), nine contraindications to inject ethanol owing to saline solution leakage, indicating rupture of the cyst during flushing (six single EST procedures and two double EST procedures in the second endometrioma and one

Table 1. Characteristics of women who have undergone transvaginal ethanol endometrioma sclerotherapy.

	N = 126
Age (years)	31.9 ± 5.5
Gravidity	0.6 ± 1.1
Parity	0.3 ± 0.8
BMI (kg/m ²)	22.9 ± 4.1
Tobacco smoker > 10 cigarettes	11 (8.7)
Serum AMH (ng/ml)	3.0 ± 2.8
AFC	11.1 ± 7.1
AFSr grade	3.6 ± 0.5
Extra ovarian endometriosis (MRI diagnosis)	88 (69.8)
Adenomyosis (MRI diagnosis)	18 (14.3)
History of operative laparoscopy for endometrioma	36 (28.6)
History of operative laparoscopy for endometriosis global treatment	19 (15.1)
Bilateral endometrioma(s)	58 (46.0)
Number of endometrioma(s)	1.9 ± 1.1
Combined transvaginal ethanol endometrioma sclerotherapy procedure with surgery for deep endometriosis	29 (23.0)

Data are mean ± SD or n (%). AFC, antral follicle count on Day 3; AMH, anti-Müllerian hormone; AFSr, American Fertility Society revised.

Table 2. Characteristics of the 157 endometriomas in 126 women who were treated using ethanol sclerotherapy.

	N = 157
Initial endometrioma(s) size (mm)	45.6 ± 20.9 40 (10; 140)
Endometrioma(s) size after EST (mm)	6.9 ± 12.9 0 (0; 78)
Initial endometrioma(s) volume (ml)	67.2 ± 124.0 25 (2; 1010)
Ethanol volume injected per endometrioma(s) (ml)	37.8 ± 124.0 15 (0; 450)
Duration of EST per endometrioma(s) (min)	10.5 ± 2.0 10 (0; 20)

Data are mean ± SD or n (%) and median (min; max). EST, ethanol sclerotherapy for endometrioma.

double EST procedure in the first endometrioma) and one contra-indication to inject ethanol in the second and third endometrioma because of failure during EST of the first endometrioma (ethanol leakage).

In 2/157 (1.3%) EST in 2/131 (1.5%) EST procedures in 2/126 (1.6%) women, a puncture was not possible because of interposition of the digestive tract. EST was suggested for pain treatment. Two women presented with a single endometrioma. The diameters of these two endometriomas were 35 and 60 mm, respectively. They had a history of endometrioma surgical resection on the same side by conventional laparoscopic surgery with divergent cystectomy traction.

For the first woman, as EST was scheduled at the same time as the surgery for associated endometriosis, cystectomy, and excision of endometriosis lesions of the Douglas, the utero-sacral ligament and the left ovarian fossa were performed after the EST failure. For the second woman, as EST was also scheduled with a laparoscopic treatment. Cystectomy and a resection of a nodule by rectal shaving was then performed.

In 2/157 (1.3%) EST in 2/131 (1.5%) EST procedures in 2/126 (1.6%) women, where the fluid was so thick that it could not be aspirated, two women presented with a single endometrioma, and EST was suggested for infertility. The diameters of these two endometriomas were 35 and 50 mm. These two women had a

history of endometriosis surgery (rectovaginal septum nodule with rectal resection for the first woman; peritoneal nodule resection, utero-sacral ligament resection, and divergent cystectomy traction for the second woman). A conventional laparoscopic surgery with divergent cystectomy traction was not performed after the failure of the EST. The IVF procedure was performed 15 days later.

In 9/157 (5.7%) EST in 9/131 (6.9%) EST procedures in 8/126 women (6.3%), saline solution leakage was found, indicating rupture of the cyst. The mean ± SD diameter of these nine endometriomas was 41.0 ± 27.6 mm. None of these women had a history of endometriosis surgery. Ethanol injection was not performed because of the risk of extravasation into the pelvis. For each woman, an alternative treatment was suggested according to indications of EST, medical history, and woman preference.

Complications

Over the 157 EST during 131 EST procedures in 126 women, a complication was reported for 15/157 (9.5%) EST in 13/131 (9.9%) EST procedures in 13/126 (10.3%) women.

Nine of 126 women (7.1%) had a grade I complication, one (0.8%) had a grade II complication, two (1.6%) had a grade II complication, and one (0.8%) had a grade IV complication. We did not find any grade V complications (Table 3).

Ethanol loss

Ethanol loss was reported in 10/131 (7.6%) EST procedures. Median blood alcohol level was 0.39 (0.12; 2.38) g/l. In one woman with two ESTs planned in the same procedure, the second EST was not performed because ethanol loss was diagnosed during the first one.

One woman had to be admitted to an intensive care unit because of an ethanol intoxication (2.38 g/l maximum), which led to coma. Her blood alcohol level was normalized in <24 h. After physiotherapy, she was allowed to go home within 48 h. She was a 42-year-old woman with stage 4 American Fertility Society revised classification of endometriosis (AFSr). She had a history of adenomyosis, adhesion between the anterior wall of the rectum, the sigmoid, and the left uterosacral ligament. She had no history of endometriosis surgery. The mean diameter of the endometrioma was 98 mm. The volume of the endometriotic fluid removed was 260 ml, and the ethanol volume injected was 120 ml. The ethanol loss was 95 ml.

Other characteristics of ethanol loss EST complications are presented in Table 3.

Septic complication

Regarding the septic complications, they occurred in a total of 3/131 (2.3%) EST procedures in 3/126 (2.4%) women. In 1/131 (0.8%) EST procedures and 1/126 (0.8%) women, medical treatment for suspicion of pelvic infection was needed. In 2/131 (1.5%) EST procedures and 2/126 (1.6%) women, surgical treatment for pelvic abscess was required.

The first woman required medical treatment. She was 32 years old with rAFS stage 3 endometriosis. She had a history of uterosacral ligament endometriosis but no history of endometriosis surgery. The mean diameter of the endometrioma was 25 mm. The volume of the endometriotic fluid removed was 10 ml, and the ethanol volume injected was 6 ml. The woman presented with abdominal pain and pain on uterine mobilization 4 days after the EST procedure with a biological inflammatory syndrome. Her symptoms were normalized after 7 days of oral antibiotics.

Table 3. Characteristics of complications associated with transvaginal ethanol sclerotherapy for endometrioma.

Grade complication	Number of endometrioma treated during EST procedure (n = 15)	Mean size of endometrioma treated (mm)	Amount of alcohol injected (ml)	Type of complication	Maximum blood alcohol level (g/l)
Grade I 9 (60.0)	1	34	12	Loss of 5 ml of ethanol	0.12
	2	33	13	Immediate stop of the EST procedure for breathing difficulties	0.18
		2	7	Loss of 5 ml of ethanol	
	1	65	58	Loss of 7 ml of ethanol	0.28
	1	64	82	Loss of 30 ml of ethanol	0.51
	1	50	31	Loss of 20 ml of ethanol	0.50
	1	60	44	Loss of 11 ml of ethanol	0.20
	1	25	21	Loss of 10 ml of ethanol	0.22
	1	71	95	Loss of 40 ml of ethanol	1.09
				(0.80 at H + 2)	
Grade II 1 (6.7)	1	120	300	Loss of 70 ml of ethanol	1.64
	1	25	10	Fever and pelvic pain. Biological inflammatory syndrome, treated by antibiotics	0.00
Grade III 2 (13.3)	2	56	90	Ovarian abscess treated with surgery and antibiotics	0.00
	1	35	14	Ovarian abscess treated with surgery and antibiotics	0.00
Grade IV 1 (6.7)	1	78	60	Ovarian abscess treated with surgery and antibiotics	0.00
Grade IV 1 (6.7)	1	98	120	Loss of 30 ml of ethanol Woman not waking up, after surgery, alcoholic coma, treating with physiotherapy, requiring ICU management	2.38

Data are mean ± SD or n (%). EST, ethanol sclerotherapy for endometrioma; ICU, intensive care unit.

The second woman required surgical treatment for a pelvic abscess. She was 43 years old with rAFS stage 4 endometriosis. She had no history of endometriosis surgery. She had undergone salpingectomy for ectopic pregnancy on the same side (right) a few months previously. There was no left hematosalpinx at the time of this laparoscopy. The mean diameter of the endometriomas was 56 mm. The mean volume of the endometriotic fluid removed was 149 ml, and the ethanol volume injected was 89 ml.

She presented with fever, pelvic pain, and biological inflammatory syndrome 7 days after the EST procedure. A contralateral ovarian abscess was diagnosed. After 48 h of i.v. antibiotics and no clinical improvement, surgical treatment was performed. Additional antibiotic therapy was completed for a total of 14 days. She did not experience a recurrence of the abscess.

The third woman also required surgical treatment for a pelvic abscess. She was 31 years old with rAFS stage 3 endometriosis. She had no history of endometriosis surgery. The mean diameter of the endometriomas was 78 mm. The mean volume of the endometriotic fluid removed was 125 ml, and the ethanol volume injected was 75 ml. Additional surgery after EST was performed in the same procedure by laparoscopic resection of rectovaginal septum.

She presented with fever, pelvic pain, unusual vaginal loss, and biological inflammatory syndrome 8 days after the EST procedure. An ovarian abscess was diagnosed. After 48 h of i.v. antibiotics and no clinical improvement, surgical treatment was performed. Additional antibiotic therapy was completed for a total of 14 days. She also did not experience a recurrence of the abscess.

The details of the endometriomas and EST procedure characteristics of all EST complications are presented in Table 3.

The maximum doses of ethanol to be injected according to weight to avoid reaching a blood ethanol concentration of 2 g/l in women are presented in Table 4.

Discussion

Based on our study results, the incidence of EST failure is low, occurring in 13/126 (10.3%) women. These failures were principally related to a contraindication in following the EST procedure of ethanol injection because saline solution leakage was identified, indicating that the cyst had ruptured during flushing (9/131 (6.9%)). Other causes of failure included 2/131 (1.5%) interpositions of the digestive tract, 2/131 (1.5%) failures to aspirate the endometriotic fluid because it was too thick or contained solid clotted parts, and 1/131 (0.8%) contraindication to performing EST on the second and third endometriomas resulting from a failure of EST on the first endometrioma. The classification of suspicion of ethanol leakage as a failure can be debated as a complication rather than a failure. However, not all woman with suspected ethanol leakage developed complications. Moreover, according to the meta-analysis of Kim et al. (2021), sclerotherapy lasting <10 min can be considered as incomplete treatment.

EST complications are represented by a few cases (10/126 (7.9%) women) of high blood alcohol levels during the EST procedure and infectious complications (3/126 (2.4%) women). Symptoms of ethanol intoxication by alcohol are well studied and usually related to blood alcohol concentration (Mendes et al., 2023). At a blood alcohol concentration higher than 3.0 g/l (65.1 mmol/l), there is an increased risk of respiratory depression and arrest. Death attributable to acute alcohol intoxication generally occurs at a blood alcohol concentration higher than 5.0 g/l (108.5 mmol/l), although the lethal dose of alcohol can be variable (Vonghia et al., 2008). However, the long-term effects of a single acute ethanol intoxication, apart from lethal effects, are difficult to establish (D'Angelo et al., 2022).

As most complications are represented by ethanol diffusion during the EST procedure, blood alcohol level analysis after EST should be suggested in case of ethanol loss to optimize patient management and avoid major clinical complications. Ethanol

Table 4. Maximum dose of ethanol to be injected according to weight to avoid reaching a blood ethanol concentration of 2 g/l in women.*

Weight (kg)	Ethanol volume (ml)	Weight (kg)	Ethanol volume (ml)	Weight (kg)	Ethanol volume (ml)	Weight (kg)	Ethanol volume (ml)	Weight (kg)	Ethanol volume (ml)
40	58	60	87	80	116	100	145	120	174
41	60	61	88	81	117	101	146	121	175
42	61	62	90	82	119	102	148	122	177
43	62	63	91	83	120	103	149	123	178
44	64	64	93	84	122	104	151	124	180
45	65	65	94	85	123	105	152	125	181
46	67	66	96	86	125	106	154	126	183
47	68	67	97	87	126	107	155	127	184
48	70	68	99	88	127	108	157	128	185
49	71	69	100	89	129	109	158	129	187
50	72	70	102	90	130	110	159	130	188
51	74	71	103	91	132	111	161	131	190
52	75	72	104	92	133	112	162	132	191
53	77	73	106	93	135	113	164	133	193
54	78	74	107	94	136	114	165	134	194
55	80	75	109	95	138	115	167	135	196
56	81	76	110	96	139	116	168	136	197
57	83	77	112	97	141	117	169	137	198
58	84	78	113	98	142	118	171	138	200
59	86	79	115	99	143	119	172	139	201

* 2 g/l corresponds to the level of severe acute alcohol intoxication, which also corresponds to the blood alcohol threshold we observed for the complications that occurred in our study.

diffusion may be explained by leakage of ethanol during procedure or intravascular absorption of ethanol by the wall cyst. This may explain cases of ethanol loss without leakage during procedure. Only one woman out of the 126 (0.8%) in our cohort had an ethanol intoxication leading to a complication with clinical relevance (coma). Her maximum blood alcohol level was 2.38 g/l and the ethanol loss was 30 ml.

In order to limit this type of complication and never to risk a Clavien–Dindo V complication, we advise practitioners to be careful with the quantity of ethanol injected.

Future studies will need to determine the maximum quantity of ethanol injection, probably in relation to the patient's weight. Blood alcohol levels are known to depend on the woman's weight (Gullberg and Jones, 1994).

An EST procedure above 80 mm should be reserved for reference centers with the expertise to handle these complications. An EST procedure in this specific case should only be proposed if the operative risks of conventional laparoscopic surgery with divergent cystectomy traction are high, after discussion with the woman, and after being approved in multidisciplinary meeting.

The intraoperative use of a noninvasive method of blood alcohol measurement could be effective for the early detection of ethanol loss. Indirectly monitoring the blood alcohol level via transdermal detection by metal oxide gas sensors can be a good method to rapidly evaluate blood alcohol concentration during an EST procedure (Annanouch et al., 2021).

Even though we performed antibiotic prophylaxis with 2 g Cefazolin and required a negative vaginal swab within 5 days prior to the EST procedure, infectious complications were still present. As when oocyte retrieval is performed for IVF, endometriosis appears to be a risk factor for infection, as does a history of pelvic inflammatory disease, ruptured appendicitis, or multiple prior pelvic surgical EST procedures (Pereira et al., 2016). Ovarian abscesses lead to infertility even when surgical management of the abscess is undertaken (Rosen et al., 2009). Pelvic infections are also a source of tubal infertility because of the salpingitis and pelvic adhesions they induce (Mårdh, 2004). Moreover, the presence of a tubo-ovarian abscess following oocyte retrieval corresponds to a 30% reduction in ovarian response

to gonadotrophin stimulation, as described by Fouks et al. (2019a). Even if antibiotic prophylaxis is not recommended for good practice in ultrasound oocyte retrieval (D'Angelo et al., 2019), it would be interesting to carry out post-operative antibiotic therapy to reduce this risk and prevent any fertility impairment in this population of infertile women (Fouks et al., 2019b).

For one woman who required surgical treatment for a pelvic abscess, an additional surgery after EST was performed in the same procedure by laparoscopic resection of rectovaginal septum. It is difficult to conclude whether the postoperative complication was related to the EST or to the laparoscopy. As it is not possible to specify the cause of the complication, it seems ethically acceptable to us to attribute it to EST.

We did not find any bleeding complications in our population even though this is one of the most common complications of oocyte punctures as a result of direct trauma to the vaginal vessels (Evers et al., 1988) and may be present in 1.4–18.4% of cases (El-Shawarby et al., 2004).

In the meta-analysis of Kim et al. involving 1301 women and 28 studies, the major complication rate of EST was between 0.0% and 7.1% in women, with a pooled estimate of 1.7% (95% CI, 1.0–2.8%). The only major complication was an abscess in 0.3% (3/1117) of the women. Subgroup analysis showed sclerotherapy >10 min for a pooled major complication rate of 1.8% (95% CI, 1.0–3.2%), which was comparable to a rate of 1.6% (95% CI, 0.6–3.9%; $P = 0.837$) for sclerotherapy ≤10 min.

The minor complication rate of sclerotherapy was between 0.0% and 36.8%, with a pooled estimate of 11.0% (95% CI, 7.1–16.5%) (Kim et al., 2021). Alcohol intoxication was less common (0.6%), probably owing to the lack of data. Abdominal ethanol extravasation was found in 0.3% of cases and pelvic inflammation in 0.2% (Kim et al., 2021).

The severity of complications during EST is comparable with that found for the non-gynecological use of sclerotherapy. In the treatment of renal cysts (Mohsen and Gomha, 2005), no severe complication was noted, and the only complications were microscopic hematuria and slight fever. In the treatment of thyroglossal duct cysts in adults (Chow et al., 2012), the only complication

was moderate pain after the EST procedure in two women, which was controlled with oral analgesics.

The aim is therefore to reduce the incidence of complications. The size of the endometrioma to be treated needs to be considered in light of the operator's experience. We started with endometriomas of <80 mm, then 100 mm, then up to 140 mm.

In our study, we treated endometriomas from 10 mm up to 140 mm and injected ethanol from 1 ml up to 540 ml. In the meta-analyses of Kim *et al.*, the lower volume of ethanol injected reported was 3 ml. Most of the studies did not report the maximum and minimum volumes of ethanol injected.

A limit for the volume of ethanol injected needs to be suggested. We propose to use the Widmark formula to calculate the limit of ethanol injected according to the woman's weight to avoid the risk of severe acute alcohol intoxication (Vonghia *et al.*, 2008). According to this formula, the maximum quantity of 96% ethanol to be injected so as not to reach 2 g/l depending on the weight of the woman is calculated as follows $C = 100vzd/rM$ (C = maximum blood alcohol concentration (mg/100 ml); M = mass of the subject (kg); r = volume of distribution of ethanol or Widmark factor (l/kg); v = volume of alcoholic beverage consumed (ml); z = strength of alcoholic beverage (% v/v); d = density of ethanol (g/ml)) (von Burg, 1982). We recommend using Table 4 to determine the maximum dose of ethanol to be injected according to the woman's weight to not reach 2 g/l blood alcohol level.

Treatment of endometriomas larger than 80 mm is a challenge. The laparoscopic approach is also complicated for these women. We have been able to treat such large endometriomas because we have long experience of EST and a facility adapted to the management of complications. We do not recommend EST over 80 mm outside referral centers, unless after discussion with the woman and being approved in a multidisciplinary team meeting. Specific research on this issue is currently being conducted by our team.

EST is easy to perform, allows outpatient treatment, and requires minimal equipment (Miquel *et al.*, 2021). It makes possible the management of isolated endometriomas by avoiding laparoscopic surgery, which is more invasive, requires a longer recovery and poses a higher risk of complications (García-Tejedor *et al.*, 2020). Moreover, using the vaginal method, EST does not present any aesthetic inconvenience.

Women suffering from endometriosis sometimes undergo complex surgical procedures. Treatment with sclerotherapy can avoid additional invasive surgery that can lead to further complications and a multiadherent pelvis (Wilde *et al.*, 2017).

In our previous study, we found that EST is also a feasible technique to improve IVF success rates in women with moderate to severe endometriosis (Miquel *et al.*, 2020).

The meta-analysis of Kim *et al.* (2021), as well as the article of Ghasemi Tehrani *et al.* (2022), provide reassuring evidence regarding the benefits and risks of EST for endometrioma. These publications, along with the 2022 guidelines from ESHRE, are starting to acknowledge the potential of EST in the management of endometrioma (The ESHRE Guideline Group on Female Fertility Preservation *et al.*, 2020).

The literature suggests that EST effectively reduces the size of endometrioma, alleviates symptoms, and improves fertility outcomes. Kim's meta-analysis provides a comprehensive evaluation of multiple studies and confirms the efficacy of EST in reducing endometrioma size and relieving associated pain (Kim *et al.*, 2021).

A study of Ghasemi Tehrani *et al.* (2022) compared the effectiveness of sclerotherapy versus laparoscopic surgery in the treatment of ovarian endometriomas, considering endometrioma recurrence rates and ovarian reserve markers such as anti-Müllerian hormone (AMH). The authors found that the recurrence rate of endometriomas was similar between the groups. However, in the laparoscopy group, a significant decrease in AMH levels was observed after 12 months (2.48 ± 1.34 versus 1.62 ± 1.22 ; $P < 0.001$), while in the sclerotherapy group, no significant changes were found between pre- and 12 months for post-operative AMH levels (2.12 ± 1.05 versus 2.09 ± 1.01 ; $P = 0.120$). These results are consistent with those of Raffi *et al.* (2012), who concluded that laparoscopic endometrioma surgery led to decreased AMH levels, which could lead to impaired fertility in women after surgery. The authors concluded that EST seems to be an effective alternative to laparoscopic surgery in the management of endometriomas and limits the alteration of ovarian reserve.

As a decision to treat must depend on the balance between benefits and risks, it would have been interesting in our study to report on clinical improvement, ovarian marker evolution, and recurrence rate after treatment, especially for the pain indication. Other articles deal specifically with this subject (Crestani *et al.*, 2023; Vaduva *et al.*, 2023). One major limitation of our study is that we opted for a study only evaluating the safety and feasibility of the method.

Notably, there is still a dearth of data suggesting a short-, medium-, or long-term superiority of EST compared to laparoscopic surgery.

At the start of our study in 2013, laparoscopic sclerotherapy was not a reported technique. We chose the EST option because this technique was well described in the early years. Laparoscopic sclerotherapy was first described in May 2020 by De Cicco Nardone *et al.* (2020) and later standardized by Crestani *et al.* (2023). According to De Cicco Nardone *et al.* (2020), the laparoscopic sclerotherapy technique seems to be an important topic of research and should be investigated further over the coming years. For the time being, the technique has been evaluated much less than EST and clinicians are less experienced in the technique than EST. No study has reported the complication rate for laparoscopic sclerotherapy.

Our study is the first to evaluate the complications of transvaginal EST with such a large cohort of women in a standardized protocol. The wider cohort of EST for endometrioma reported in the meta-analysis of Kim *et al.* (2021) is that of Wang *et al.* (2011), with 68 women with EST short-term retention (10 min) and 69 women with EST retention (no re-aspiration). No complication was noticed in the study, probably owing to publication bias.

In addition, we included women with large endometriomas of up to 140 mm and 1010 ml, whereas previous studies rarely dealt with such large sizes. In the meta-analysis of García-García *et al.* (2022), the maximum size of benign-appearing adnexal cystic mass treated by EST was 120 mm, with a maximum volume of 300 ml.

In conclusion, sclerotherapy is a reliable, minimally invasive method applicable as an outpatient procedure but also associated with a risk of ethanol intoxication. This risk was low in our study, but it can expose women to a life-threatening condition. We suggest that clear information on this risk must be provided to women. To reduce these complications, we propose to systematically perform an evaluation of ethanol loss during the procedure and perform blood alcohol level analysis if ethanol leakage is suspected. The steps of the procedure should be respected to

avoid the dissemination of ethanol and the risks of ethanol intoxication. This will allow rapid and appropriate management of intraoperative complications. Specific training in sclerotherapy is required, as well as periodic monitoring of assessing its complications (leak rate, average ethanol loss, overall complications). We do not believe that it is appropriate to perform EST on endometriomas wider than 80 mm outside a center specialized in endometriosis and management of the specific complications of sclerotherapy.

Any indication for sclerotherapy should be decided after a multidisciplinary team meeting to assess other treatment options and the benefit/risk balance.

Authors' roles

J.L. and L.M. wrote the original draft and analyzed the data. A.P., A.N., and B.C. conducted the investigations and provided study material resources. A.A. review and edited the draft, did the conceptualization, and directed the project. All authors revising the draft critically and agree to submission of the final article.

Funding

None.

Conflict of interest

There are no conflicts of interest to declare.

References

Aboulgar MA, Mansour RT, Serour GI, Sattar M, Ramzy AM, Amin YM. Treatment of recurrent chocolate cysts by transvaginal aspiration and tetracycline sclerotherapy. *J Assist Reprod Genet* 1993; **10**:531–533.

Agostini A, De Lapparent T, Collette E, Capelle M, Cravello L, Blanc B. In situ methotrexate injection for treatment of recurrent endometriotic cysts. *Eur J Obstet Gynecol Reprod Biol* 2007; **130**:129–131.

Akamatsu N, Hirai T, Masaoka H, Sekiba K, Fujita T. [Ultrasonically guided puncture of endometrial cysts—aspiration of contents and infusion of ethanol]. *Nihon Sanka Fujinka Gakkai Zasshi* 1988; **40**:187–191.

Annanouch FE, Martini V, Fiorido T, Lawson B, Aguir K, Bendahan M. Embedded transdermal alcohol detection via a finger using SnO₂ gas sensors. *Sensors (Basel)* 2021; **21**:6852.

Chapron C, Marcellin L, Borghese B, Santulli P. Rethinking mechanisms, diagnosis and management of endometriosis. *Nat Rev Endocrinol* 2019; **15**:666–682.

Chapron C, Vercellini P, Barakat H, Vieira M, Dubuisson J-B. Management of ovarian endometriomas. *Hum Reprod Update* 2002; **8**:591–597.

Chow T-L, Choi C-Y, Yee-Hing Hui J. Thyroglossal duct cysts in adults treated by ethanol sclerotherapy: a pilot study of a non-surgical technique. *Laryngoscope* 2012; **122**:1262–1264.

Cohen A, Almog B, Tulandi T. Sclerotherapy in the management of ovarian endometrioma: systematic review and meta-analysis. *Fertil Steril* 2017; **108**:117–124.e5.

Crestani A, Merlot B, Dennis T, Chanavaz-Lacheray I, Roman H. Impact of laparoscopic sclerotherapy for ovarian endometriomas on ovarian reserve. *J Minim Invasive Gynecol* 2023; **30**:32–38.

Crestani A, Merlot B, Dennis T, Roman H. Laparoscopic sclerotherapy for an endometrioma in 10 steps. *Fertil Steril* 2022; **117**:1102–1103.

D'Angelo A, Panayotidis C, Amso N, Marci R, Matorras R, Onofriescu M, Turp AB, Vandekerckhove F, Veleva Z, Vermeulen N et al.; ESHRE Working Group on Ultrasound in ART. Recommendations for good practice in ultrasound: oocyte pick up. *Hum Reprod Open* 2019; **2019**:hoz025.

D'Angelo A, Petrella C, Greco A, Ralli M, Vitali M, Giovagnoli R, De Persis S, Fiore M, Ceccanti M, Messina MP. Acute alcohol intoxication: a clinical overview. *Clin Ter* 2022; **173**:280–291.

De Cicco Nardone A, Carfagna P, De Cicco Nardone C, Scambia G, Marana R, De Cicco Nardone F. Laparoscopic ethanol sclerotherapy for ovarian endometriomas: preliminary results. *J Minim Invasive Gynecol* 2020; **27**:1331–1336.

Dindo D, Demartines N, Clavien P-A. Classification of surgical complications: a new proposal with evaluation in a cohort of 6336 patients and results of a survey. *Ann Surg* 2004; **240**:205–213.

El-Shawarby SA, Margara RA, Trew GH, Lavery SA. A review of complications following transvaginal oocyte retrieval for in-vitro fertilization. *Hum Fertil (Camb)* 2004; **7**:127–133.

Eskenazi B, Warner ML. EPIDEMIOLOGY OF ENDOMETRIOSIS. *Obstet Gynecol Clin North Am* 1997; **24**:235–258.

Evers JL, Larsen JF, Gnany GG, Sieck UV. Complications and problems in transvaginal sector scan-guided follicle aspiration. *Fertil Steril* 1988; **49**:278–282.

Fouks Y, Azem F, Many A, Cohen Y, Levin I, Cohen A. Fertility outcomes in patients with tubo-ovarian abscesses after an oocyte retrieval: a longitudinal cohort analysis. *Arch Gynecol Obstet* 2019a; **300**:763–769.

Fouks Y, Cohen Y, Tulandi T, Meiri A, Levin I, Almog B, Cohen A. Complicated clinical course and poor reproductive outcomes of women with tubo-ovarian abscess after fertility treatments. *J Minim Invasive Gynecol* 2019b; **26**:162–168.

García-García I, Alcázar JL, Rodríguez I, Pascual MA, Garcia-Tejedor A, Guerriero S. Recurrence rate and morbidity after ultrasound-guided transvaginal aspiration of ultrasound benign-appearing adnexal cystic masses with and without sclerotherapy: a systematic review and meta-analysis. *J Minim Invasive Gynecol* 2022; **29**:204–212.

García-Tejedor A, Martínez-García J, Candas M, Suarez B, Mañalich E, Gomez L, Merino M, Castellarnau E, Regueiro M, Carreras P et al. Ethanol sclerotherapy versus laparoscopic surgery for endometrioma treatment: a prospective, multicenter, cohort pilot study. *J Minim Invasive Gynecol* 2020; **27**:1133–1140.

García-Velasco JA, Somigliana E. Management of endometriomas in women requiring IVF: to touch or not to touch. *Hum Reprod* 2009; **24**:496–501.

Ghasemi Tehrani H, Tavakoli R, Hashemi M, Haghighat S. Ethanol sclerotherapy versus laparoscopic surgery in management of ovarian endometrioma; a randomized clinical trial. *Arch Acad Emerg Med* 2022; **10**:e55.

Gullberg RG, Jones AW. Guidelines for estimating the amount of alcohol consumed from a single measurement of blood alcohol concentration: re-evaluation of Widmark's equation. *Forensic Sci Int* 1994; **69**:119–130.

Hart RJ, Hickey M, Maouris P, Buckett W. Excisional surgery versus ablative surgery for ovarian endometriomata. *Cochrane Database Syst Rev* 2008; **CD004992**.

Hsieh C-L, Shiao C-S, Lo L-M, Hsieh T-T, Chang M-Y. Effectiveness of ultrasound-guided aspiration and sclerotherapy with 95%

- ethanol for treatment of recurrent ovarian endometriomas. *Fertil Steril* 2009;**91**:2709–2713.
- Kim GH, Kim PH, Shin JH, Nam IC, Chu HH, Ko H-K. Ultrasound-guided sclerotherapy for the treatment of ovarian endometrioma: an updated systematic review and meta-analysis. *Eur Radiol*. 2021;**32**:1726–1737.
- Mårdh P-A. Tubal factor infertility, with special regard to chlamydial salpingitis. *Curr Opin Infect Dis* 2004;**17**:49–52.
- Mendes PFS, Baia-da-Silva DC, Melo WWP, Bittencourt LO, Souza-Rodrigues RD, Fernandes LMP, Maia CDSF, Lima RR. Neurotoxicology of alcohol: a bibliometric and science mapping analysis. *Front Pharmacol* 2023;**14**:1209616.
- Miquel L, Preaubert L, Gnisci A, Netter A, Courbiere B, Agostini A, Pivano A. Transvaginal ethanol sclerotherapy for an endometrioma in 10 steps. *Fertil Steril* 2021;**115**:259–260.
- Miquel L, Preaubert L, Gnisci A, Resseguier N, Pivano A, Perrin J, Courbiere B. Endometrioma ethanol sclerotherapy could increase IVF live birth rate in women with moderate-severe endometriosis. *PLoS One* 2020;**15**:e0239846.
- Mohsen T, Gomha MA. Treatment of symptomatic simple renal cysts by percutaneous aspiration and ethanol sclerotherapy. *BJU Int* 2005;**96**:1369–1372.
- Nezhat C, Crowgey S, Nezhat F. Videolaseroscopy for the treatment of endometriosis associated with infertility. *Fertil Steril* 1989;**51**:237–240.
- Pereira N, Hutchinson AP, Lekovich JP, Hobeika E, Elias RT. Antibiotic prophylaxis for gynecologic procedures prior to and during the utilization of assisted reproductive technologies: a systematic review. *J Pathog* 2016;**2016**:4698314.
- Raffi F, Metwally M, Amer S. The impact of excision of ovarian endometrioma on ovarian reserve: a systematic review and meta-analysis. *J Clin Endocrinol Metab* 2012;**97**:3146–3154.
- Rosen M, Breitkopf D, Waud K. Tubo-ovarian abscess management options for women who desire fertility. *Obstet Gynecol Surv* 2009;**64**:681–689.
- Roustan A, Perrin J, Debals-Gonthier M, Paulmyer-Lacroix O, Agostini A, Courbiere B. Surgical diminished ovarian reserve after endometrioma cystectomy versus idiopathic DOR: comparison of in vitro fertilization outcome. *Hum Reprod* 2015;**30**:840–847.
- Shawki HE, Elmorsi M, Samir A, Eissa MK. In situ methotrexate injection after transvaginal ultrasound-guided aspiration of ovarian endometriomas: a randomized controlled trial. *Middle East Fert Soc J* 2011;**16**:224–231.
- The ESHRE Guideline Group on Female Fertility Preservation; Anderson RA, Amant F, Braat D, D'Angelo A, Chuva de Sousa Lopes SM, Demeestere I, Dwek S, Frith L, Lambertini M et al. ESHRE guideline: female fertility preservation. *Hum Reprod Open* 2020;**2020**:hoaa052.
- Vaduva CC, Dira L, Carp-Veliscu A, Goganau AM, Ofiteru AM, Siminel MA. Ovarian reserve after treatment of ovarian endometriomas by ethanolic sclerotherapy compared to surgical treatment. *Eur Rev Med Pharmacol Sci* 2023;**27**:5575–5582.
- Vercellini P, Fedele L, Aimi G, De Giorgi O, Consonni D, Crosignani PG. Reproductive performance, pain recurrence and disease relapse after conservative surgical treatment for endometriosis: the predictive value of the current classification system. *Hum Reprod* 2006;**21**:2679–2685.
- von Burg R. E. M. P. Widmark, Principles and applications of medico-legal alcohol determination translated from the original publication in 1932 by R. C. Baselt. Biomedical Publications, Davis California, 166 pp. *J Appl Toxicol* 1982;**2**:IV–IV.
- Vonghia L, Leggio L, Ferrulli A, Bertini M, Gasbarrini G, Addolorato G; Alcoholism Treatment Study Group. Acute alcohol intoxication. *Eur J Intern Med* 2008;**19**:561–567.
- Wang L-L, Dong X-Q, Shao X-H, Wang S-M. Ultrasound-guided interventional therapy for recurrent ovarian chocolate cysts. *Ultrasound Med Biol* 2011;**37**:1596–1602.
- Wang S-M, Cai H-Q, Dong X-Q, Fan Q-L, Wang L-L, Shao X-H, Zhang L-W. Correlation between ovarian chocolate cyst and serum carbohydrate antigen 125 level and the effect of ultrasound-guided interventional sclerotherapy on serum carbohydrate antigen 125 level. *J Obstet Gynaecol Res* 2015;**41**:92–98.
- Wilde RLD, Alvarez J, Brolmann H, Cheong Y, Collinet P, Sardo ADS, Koninckx P, Lunderoff P, Pawelczyk L, Roche L et al. Awareness of post-surgical adhesions among gynecological surgeons: focus on the surgical management of endometriosis. *Ann Med Health Sci Res* 2017;**7**:13–17.
- Yazbeck C, Koskas M, Cohen Scali S, Kahn V, Luton D, Madelenat P. How I do ... ethanol sclerotherapy for ovarian endometriomas. *Gynecol Obstet Fertil* 2012;**40**:620–622.
- Yazbeck C, Madelenat P, Ayel JP, Jacquesson L, Bontoux LM, Solal P, Hazout A. Ethanol sclerotherapy: a treatment option for ovarian endometriomas before ovarian stimulation. *Reprod Biomed Online* 2009;**19**:121–125.