



**HAL**  
open science

## Risk factors associated with progression from papilloedema to optic atrophy: results from a cohort of 113 patients

Ruben Attia, Ruben Fitoussi, Kevin Mairot, Sarah Demortiere, Jan-Patrick Stellman, Penelope Tilsley, Bertrand Audoin, Thierry David, Natacha Stolowy

### ► To cite this version:

Ruben Attia, Ruben Fitoussi, Kevin Mairot, Sarah Demortiere, Jan-Patrick Stellman, et al.. Risk factors associated with progression from papilloedema to optic atrophy: results from a cohort of 113 patients. *BMJ Open Ophthalmology*, 2023, 8 (1), pp.e001375. 10.1136/bmjophth-2023-001375 . hal-04556183

**HAL Id: hal-04556183**

**<https://amu.hal.science/hal-04556183v1>**

Submitted on 23 Apr 2024

**HAL** is a multi-disciplinary open access archive for the deposit and dissemination of scientific research documents, whether they are published or not. The documents may come from teaching and research institutions in France or abroad, or from public or private research centers.

L'archive ouverte pluridisciplinaire **HAL**, est destinée au dépôt et à la diffusion de documents scientifiques de niveau recherche, publiés ou non, émanant des établissements d'enseignement et de recherche français ou étrangers, des laboratoires publics ou privés.



Distributed under a Creative Commons Attribution - NonCommercial 4.0 International License

# Risk factors associated with progression from papilloedema to optic atrophy: results from a cohort of 113 patients

Ruben Attia ,<sup>1</sup> Ruben Fitoussi,<sup>1</sup> Kevin Mairot,<sup>1</sup> Sarah Demortiere,<sup>2</sup> Jan-Patrick Stellman,<sup>3</sup> Penelope Tilsley,<sup>3</sup> Bertrand Audoin,<sup>2</sup> Thierry David ,<sup>1</sup> Natacha Stolowy<sup>1</sup>

**To cite:** Attia R, Fitoussi R, Mairot K, *et al*. Risk factors associated with progression from papilloedema to optic atrophy: results from a cohort of 113 patients. *BMJ Open Ophthalmology* 2023;**8**:e001375. doi:10.1136/bmjophth-2023-001375

Received 27 June 2023  
Accepted 15 October 2023

## ABSTRACT

**Background** The aim of this study was to assess the risk factors for atrophic progression of patients with papilloedema secondary to intracranial hypertension, using optical coherence tomography parameters.

**Methods** A retrospective study was conducted at Marseille University Hospitals' Ophthalmology departments between December 2015 and December 2021. All patients with papilloedema resulting from elevated intracranial hypertension at the initial presentation were included. Ophthalmological evaluations included analysing retinal nerve fibre layer (RNFL), ganglion cell layer (GCL) and total peripapillary retinal thickness (RT).

**Results** The study included 222 eyes from 113 patients. The main aetiologies of intracranial hypertension were idiopathic intracranial hypertension (49/113), intracranial tumours (33/113) and cerebral venous thrombosis (15/113). The initial RNFL and RT showed significant correlations with optic atrophy. The mean RNFL was 199.63 µm in the 'no atrophy' group and 365.28 µm in the 'atrophy' group ( $p < 0.001$ ). Similarly, the mean RT was 483.72 µm in the 'non-atrophy' group and 796.69 µm in the 'atrophy' group ( $p < 0.001$ ). The presence of peripapillary haemorrhages showed a strong correlated with optic atrophy with an OR=19.12 ( $p < 0.001$ ). Impaired initial visual acuity was also associated with final optic atrophy with an OR=7.76 ( $p = 0.020$ ). Furthermore, impaired initial GCL was a major predictor of optic atrophy (OR=18.25 ( $p = 0.021$ )).

**Conclusion** Our study highlights the risk factors for optic atrophy in papilloedema, aiming to facilitate the early detection of patients at a high risk of vision loss and enable more aggressive medical or surgical management.

## INTRODUCTION

Papilloedema is the swelling of the optic nerves, caused by increased intracranial pressure (ICP). It is a major health problem, particularly because of its disabling symptoms, its aetiologies and its complications. Indeed, papilloedema can lead to optic nerve atrophy with visual field alterations, or even permanent vision loss due to optic nerve damage if patients are not promptly and appropriately treated.<sup>1</sup>

## WHAT IS ALREADY KNOWN ON THIS TOPIC

⇒ Recognised risk factors for atrophic progression of papilloedema is the initial grade of oedema, other risk factors are poorly identified. Despite this, previous studies tend to include Frisen classification and visual acuity tests, without the use of optical coherence tomography.

## WHAT THIS STUDY ADDS

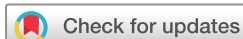⇒ This study identified risk factors for optic atrophy in papilloedema. The initial oedema grade quantifiable with optical coherence tomography, severe visual acuity decline, ganglion cell damage and peripapillary haemorrhages predict optic atrophy progression.

## HOW THIS STUDY MIGHT AFFECT RESEARCH, PRACTICE OR POLICY

⇒ It would be interesting to follow up after aggressive medical treatment those patients who show these characteristics.

Some of the main causes include idiopathic intracranial hypertension (IIH)—an increasingly common disease in our society as obesity rates increase,<sup>2</sup> brain tumours and cerebral sinus venous thrombosis. Surgical treatments for IIH—such as venous stenting or shunt surgeries—are currently only performed in refractory papilloedema and chronic stages of papilloedema. Similarly, brain tumours often do not initially require surgery. The resulting chronic elevation of ICP is highly linked to visual prognosis and presents a high threat to the patient's vision, while invasive surgery also presents a risk for vision.<sup>3,4</sup> Being able to quickly and accurately identify papilloedema with or without risk of optic nerve atrophy is thus essential for guiding neurologists, neurosurgeons and neuroradiologists in pathologies requiring a more aggressive management.

Currently, the stages of papilloedema are usually classified using a scoring system



© Author(s) (or their employer(s)) 2023. Re-use permitted under CC BY-NC. No commercial re-use. See rights and permissions. Published by BMJ.

<sup>1</sup>Ophthalmology, Hospital Timone, Marseille, France

<sup>2</sup>Neurology, Hospital Timone, Marseille, France

<sup>3</sup>Neuroimaging service, CRMBM, Marseille, France

## Correspondence to

Dr Ruben Attia; rubat@hotmail.fr

proposed by the Frisén scale.<sup>5</sup> However, this scale is susceptible to high interevaluator and intraevaluator variability.<sup>6</sup> Further, while one of the recognised risk factors for atrophic progression of papilloedema is the initial grade of oedema,<sup>7</sup> other risk factors are poorly identified. Optical coherence tomography (OCT) is a quick, non-invasive, easily quantifiable technique that could allow objective measures of papilloedema 'progression', as well as identification of risk factors for atrophic progression. It has been shown, for example, that OCT volumetric measurements of papilloedema correlate with Frisén scale grade.<sup>8</sup> Further, OCT can also help distinguish between normal optic nerve or pseudo-optic disc oedema and true optic disc oedema.<sup>9</sup> Despite this, previous studies tend to include Frisén classification and visual acuity tests, without the use of OCT.<sup>7</sup>

The aim of this study was to assess the risk factors for atrophic progression of papilloedema patients with papilloedema secondary to IH, using OCT parameters.

## METHODS

### Participants

We conducted a retrospective analysis, incorporating longitudinal follow-up data from patients with optic disc oedema who were recruited from the ophthalmology departments of Marseille University Hospitals, including both The Hospital of La Timone and North Hospital between December 2015 and December 2021. Opt-out consent was obtained from all patients. This is a method used in the recruitment of participants into research where information is provided to the potential participant regarding the research and the involvement, and where their participation is presumed unless they express to decline to participate. All patients, irrespective of age, with optic disc oedema secondary to elevated ICP at initial presentation, were included. Additional inclusion criteria were a recent diagnosis of papilloedema (less than 1 week after first finding of papilloedema if diagnosis was made with an in-office ophthalmologist), feasible OCT examination, and OCT follow-up for at least 3 months.

Exclusion criteria for correlation analyses were the absence of at least two retinal nerve fibre layer thickness (RNFL) OCT examinations from different days (patients had to have at least one follow-up 3 months after the initial visit), the presence of an ophthalmological disease or ophthalmological feature that could influence OCT imaging (eg, glaucoma, history of optic neuropathy, papillary dysversion, epiretinal membrane) or a brain tumour adjacent to the visual pathways as defined by experts from the Department of Neuroradiology at the Timone Hospital (tertiary centre).

### Clinical measures

The following clinical data were collected: age, sex, symptoms (headache, nausea, vomiting, visual blur, diplopia, tinnitus, visual eclipses, epilepsy) and their speed of onset, body mass index (BMI), aetiology of papilloedema, presence of peripapillary haemorrhage at initial presentation,

association with sixth cranial pair palsy (abducens nerve), visual field, visual acuity, opening ICP at lumbar puncture in strict lateral decubitus and therapeutic management. Initial diagnosis of IH was confirmed according to the revised Dandy criteria.<sup>10</sup>

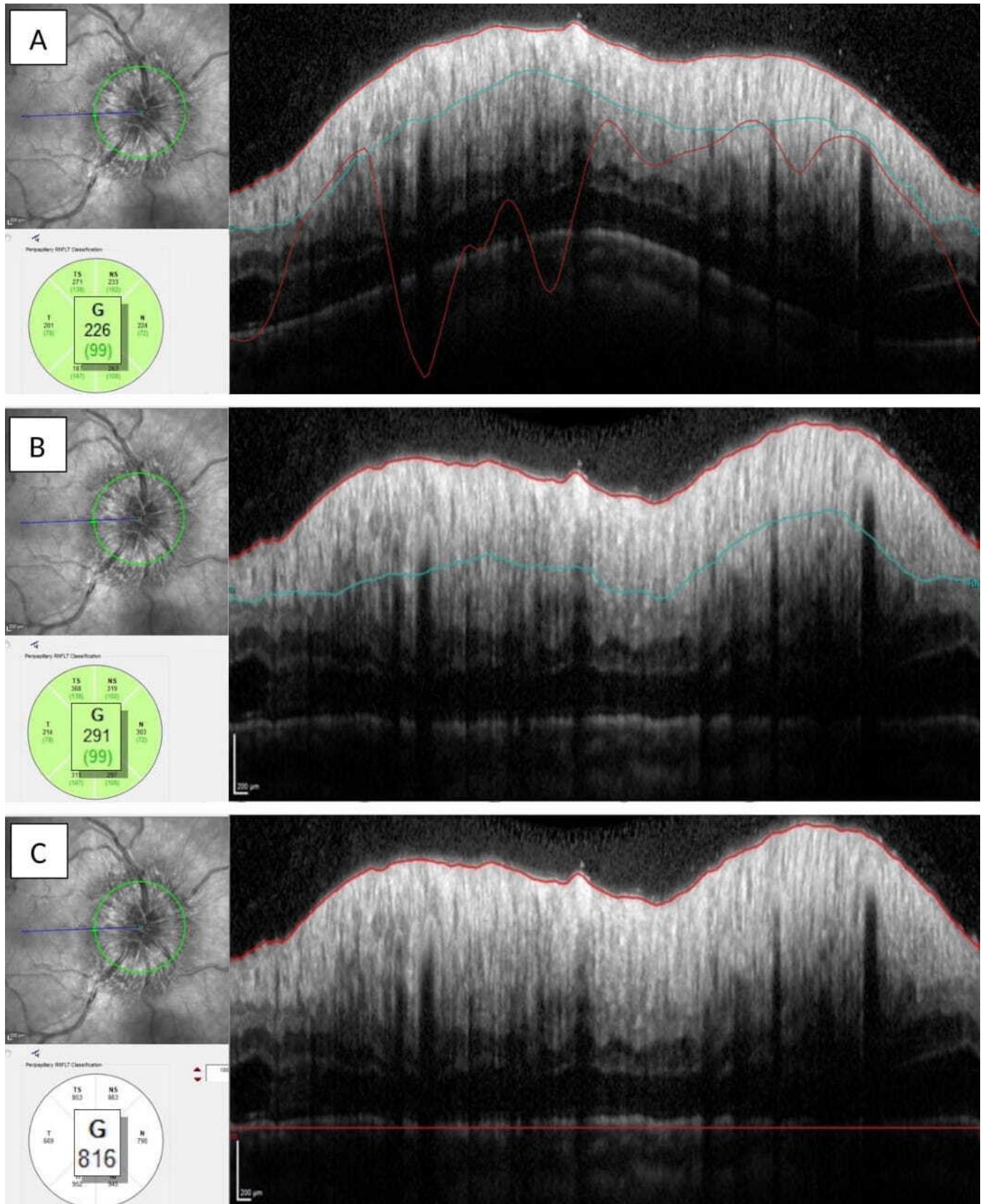
### OCT protocol

OCT data were collected using a Heidelberg Spectralis Spectral Domain OCT (Heidelberg Engineering, Germany), Spectralis software V.5.3.3.0, Eye Explorer software V.1.6.4.0. The following OCT data were collected as part of a routine clinical OCT protocol: RNFL, total peripapillary retinal thickness (TR) (TR: total retina), ganglion cell layer (GCL) and scleral canal size. The RNFL was measured using a 3.4 mm circular scan around the optic nerve with the segmentation algorithm and the standardised eye-tracking enabled device protocol (TrueTrack). The TR was measured using the same image as for the RNFL, and corresponded to the thickness between the internal limiting membrane (ILM) and Bruch's membrane (BM). RNFL and TR were automatically segmented by the device. Spectralis software of Heidelberg OCT was used to perform manual corrections of RNFL and TR segmentation when the automatic segmentation by the OCT showed incorrect layer segmentation of the ILM, RNFL or BM (figure 1). The verifications and modifications of the RNFL segmentations were performed by two ophthalmologist. The GCL was analysed when a macular OCT was available and automatically segmented by the device. It was thoroughly checked, and in cases of inaccurate automatic segmentation, the values were not considered. OCT data were collected several times during the follow-up: at diagnosis, at 3 months, at 6 months, at 12 months and at the patient's last visit.

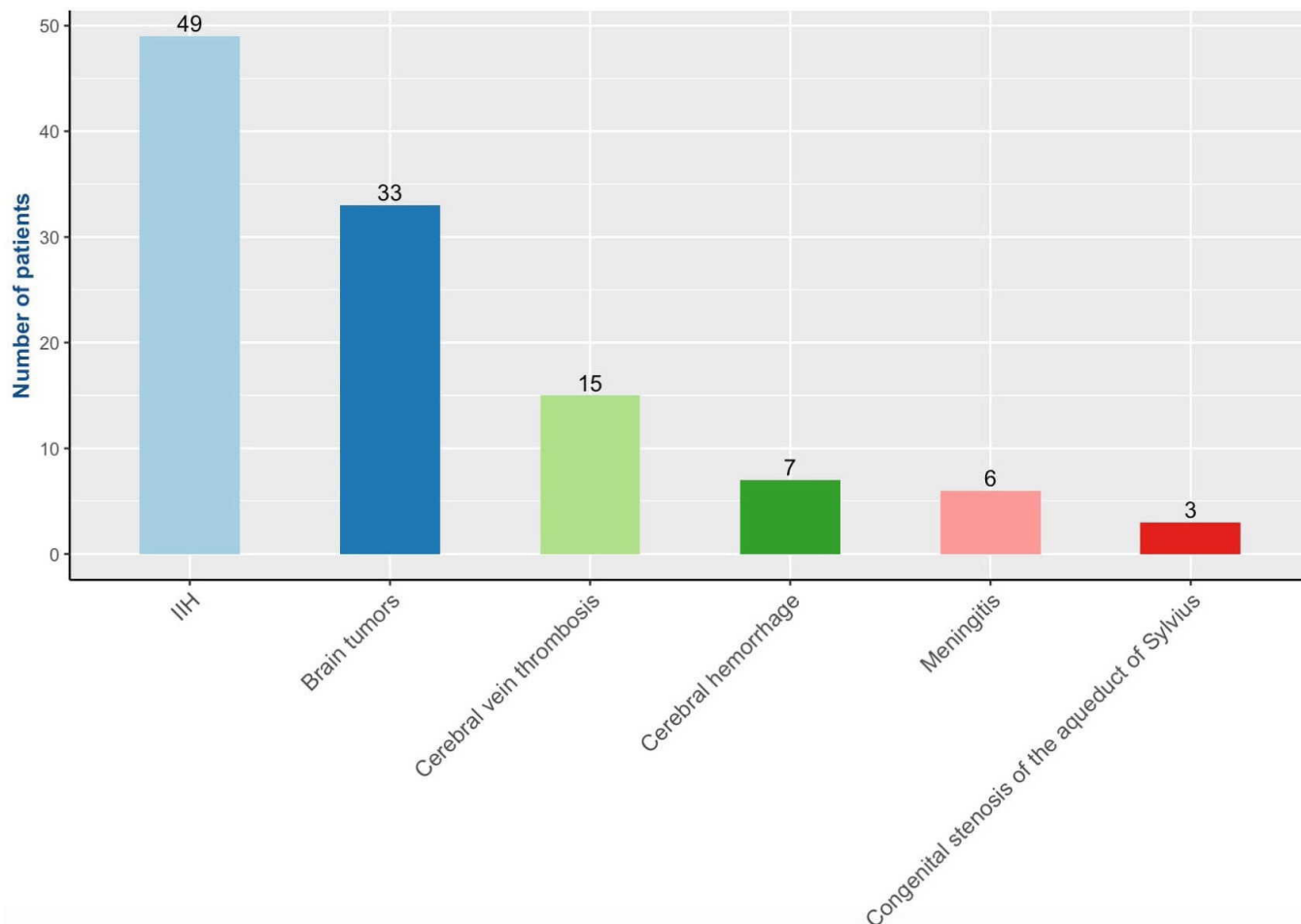
Our primary outcome measure was the presence of optic nerve atrophy defined by the presence of an RNFL beyond 95% of the OCT database CI, and/or severe sectoral atrophy defined by a value beyond 99% of the OCT database CI

### Statistical analysis

Data were analysed using RStudio software V.4.2.0 (2022-04-22 ucrt) (R Core Team 2022. R: a language and environment for statistical computing. R Foundation for Statistical Computing, Vienna, Austria) and the ggplot and dplyr packages. Descriptive results are presented using the mean±SD, minimum and maximum values, or the number and associated percentage (%) dependent on the data. Correlation analyses of quantitative variables were measured using the Pearson correlation coefficient. Analysis of the primary outcome was performed using logistic regression and Wilcoxon tests for univariate analyses, and multiple logistic regression. Relevant variables were included in the multiple model approach and were selected through a stepwise procedure using the Akaike information criterion. A  $p < 0.05$  indicated a statistically significant result.



**Figure 1** Comparison of automatic and manual segmentation of optic nerve head scans. (A) The infrared reflectance image illustrating the localisation of the 3.4 mm circular scan centred on the optic nerve head with the automatic segmentation. The automatic segmentation of internal limiting membrane (red superior), Bruch's membrane (red inferior) and RNFL (blue) is inappropriate and shows a false global thickness (G). (B, C) Equivalent segmentation images and global thickness (G) after manual correction. RNFL, retinal nerve fibre layer.



**Figure 2** Bar plot of the different aetiologies of intracranial hypertension in the cohort.

## RESULTS

### Cohort details

The study included data for 222 eyes across 113 patients with IH, 93 of whom were at La Timone Hospital and 20 at the North Hospital in Marseille, France. Data from 54 eyes were subsequently excluded from the correlation analyses: 34 were lost to follow-up due to having a follow-up of less than 3 months, 16 eyes were removed due to lack of OCT data, 3 eyes had an optic disc dysversion and 1 eye had intravitreal haemorrhage. Out of the 168 eyes finally included, 35 showed optic atrophy according to the primary outcome.

### Demographic and clinical data

The average age of the patients was 24.3 years ( $\pm 16.72$ ), with a mean BMI of 25.9 kg/m<sup>2</sup>. The majority of patients had bilateral involvement, with only four patients presenting unilateral involvement, and mean follow-up was 13.9 months. The cohort included more women (64.6%).

The various aetiologies of IH in the cohort are detailed in figure 2. The main causes of IH, accounting for more than 80% of cases, were IIH (43.36%), intracranial tumours (29.20%) and cerebral venous thrombosis (13.27%). Among the IIH cases, only 3 were classified as

fulminant, 15 as subacute and 31 as chronic. Of the intracranial tumours, these were found to be gliomas (10/33), meningiomas (5/33), cysts (5/33), medulloblastomas (3/33), craniopharyngiomas (3/33), metastases (2/33), pineal tumours (2/33), haemangioblastoma (1/33), schwannoma (1/33) and neuroblastoma (1/33). Among the gliomas, we found pilocytic astrocytomas (4/10), tectal plate gliomas (2/10), gangliogliomas (2/10), one brainstem glioma and one posterior fossa glioma.

Out of the 113 patients, 52 were children under the age of 18. The aetiologies of IH in children were primarily intracranial tumours (19/33), IIH (18/46), cerebral venous thrombosis (5/15), cerebral haemorrhages (4/7), meningitis (3/6) and congenital stenosis of the aqueduct of Sylvius (3/3).

Headache (73%) was the most common symptom. Patients had the following ophthalmologic symptoms during their illness: visual blur (35%), diplopia (19%) and visual eclipses (10%). They also described nausea and/or vomiting (37%), tinnitus (5%) and seizures (5%). Sixty patients were treated pharmacologically with acetazolamide (n=60), sometimes in combination with topiramate (n=7) or furosemide (n=1). Repeated therapeutic lumbar punctures were performed on nine

**Table 1** Evolution of the cohort\*

	Parameters	D0†	M3	M6	M12	Last follow-up
VA (logmar)	Mean±SD	0.05±0.13	0.02±0.13	0.02±0.14	0.01±0.15	0.01±0.15
RNFL (µm)	Mean±SD	232.47±108.63	115.50±30.19	105.01±30.98	100.91±20.71	100.54±19.0
n		189	145	111	91	168
TR (µm)	Mean±SD	547.48±206.47	346.77±52.36	324.04±37.75	318.28±28.68	323.24±39.03
n		189	145	111	91	168
GCL (mm <sup>3</sup> )	Mean±SD	1.14±0.10	1.11±0.14	1.08±0.14	1.10±0.14	1.10±0.14
n		159	118	91	74	145

\*As this was a retrospective cohort, not all the patients had a routine OCT at all data points.

†D0 is the day of the first consultation in the ophthalmology department.

GCL, ganglion cell layers; mean, average; n, number of patients who had the scan; OCT, optical coherence tomography; RNFL, nerve fibre layer thickness; TR, total retina; VA, visual acuity.

patients. The most frequently performed surgeries were excisional surgery (n=18), ventriculocisternostomy (n=14) and ventriculoperitoneal shunts (n=13). In rarer cases, stenting (n=1), external lumbar shunt (n=1), subdural-peritoneal shunt (n=1) and haematoma evacuation (n=1) were performed.

### Initial visual acuity and follow-up

Initial visual acuity was less than or equal to 20/25 on the Snellen scale in 14.6% of eyes. Sixty-nine per cent (87/126) of the eyes with an initial visual field test had only an enlargement of the blind spot. The visual field was normal in 9.5% of patients (12/126). Finally, 21.5% (27/126) had severe impairment such as central or para-central scotomas or even diffuse deficits.

At the time of the last follow-up, 5.4% of the eyes (12/222) had a visual acuity of 20/32 or less. Among them, three eyes had a visual acuity lower than 20/200.

### OCT follow-up

The evolution of OCT parameters (RNFL, GCL, TR) is detailed in table 1. Statistical analyses of RNFL and TR follow-up showed that papilloedema decreased significantly during the first 3 months following diagnosis. The size of the scleral canal at diagnosis was 1880.15±272.06 µm.

### Correlation between RNFL, OCT and demographic measures

Correlation analyses were performed between RNFL at last follow-up and demographic and OCT measures. Age at diagnosis, BMI and time between the appearance of first symptoms and the diagnosis were not correlated with final RNFL (table 2). A subgroup analysis in the IIH category was performed and also showed no correlation between BMI and final RNFL with a correlation coefficient of -0.19 (p=0.09).

The initial RNFL and the initial TR were significantly negatively correlated with the final RNFL with respective correlation indices of -0.65 (p<0.001) and -0.61 (p<0.001). The initial RNFL and the initial TR were also significantly negatively correlated with the final GCL, but with smaller correlation indices, respectively, -0.5 (p<0.001) and -0.45 (p<0.001).

Furthermore, we conducted correlation analyses between an initial altered GCL (defined by an initial GCL at D0 lower than 1mm<sup>3</sup>) and the final RNFL. The RNFL had an average of 102 µm in the group with intact GCL, whereas it was 78 µm in the group with altered GCL, with a p<0.01.

Other significant associations were found. Scleral canal size was moderately negatively correlated with final RNFL (cor=-0.39; p<0.01) as was opening ICP at lumbar puncture in strict lateral decubitus (cor=-0.28; p<0.01).

### Demographic and clinical risk factors for final optic nerve atrophy

Correlation analyses were performed between qualitative variables and the primary outcome (table 3). Results showed that sex was not correlated with the presence of final optic nerve atrophy in the total cohort, nor in the IIH subgroup analysis with an OR=0.84 (95% CI 0.12 to 3.73, p=0.839). Furthermore, the presence of peripapillary haemorrhages at the initial fundus was strongly

**Table 2** Univariate correlation analysis of quantitative variables against the final RNFL

	Final RNFL	
	COR	P value
Age	0.12	0.098
BMI	-0.12	0.12
Intracranial pressure*	<b>-0.28</b>	<b>&lt;0.01</b>
TR d0	<b>-0.61</b>	<b>&lt;0.00001</b>
RNFL d0	<b>-0.65</b>	<b>&lt;0.00001</b>
Scleral canal size	<b>-0.39</b>	<b>&lt;0.01</b>
Delay†	-0.13	0.11

The bold values are the significant values (p < 0.05).

\*Measured by the opening pressure at the lumbar puncture in strict lateral decubitus.

†Delay between the first symptoms and the diagnosis.

BMI, body mass index; COR, correlation coefficient; RNFL D0, retinal nerve fibre layer thickness at diagnosis; TR D0, total peripapillary retinal thickness at diagnosis.

**Table 3** Univariate and multivariate analysis of the risk factors for optic atrophy by primary outcome

	Univariate analysis			Multivariate analysis	
	OR (95% CI)		P value	OR (95% CI)	P value
Male sex	0.83 (0.34 to 1.88)		0.666		
IIH	1.00 (0.47 to 2.11)		0.996		
Haemorrhage	33.17 (11.40 to 113.85)		<b>p&lt;0.001</b>	19.12 (3.92 to 111.37)	<b>p&lt;0.001</b>
VF damage*	37.51 (10.97 to 176.88)		<b>p&lt;0.001</b>		
VA $\leq$ 20/25	25.76 (9.38 to 80.61)		<b>p&lt;0.001</b>	7.76 (1.35 to 46.39)	<b>0.020</b>
Initial GCL reach†	35.67 (5.92 to 685.24)		<b>0.001</b>	18.25 (1.94 to 416.59)	<b>0.021</b>
Cephalées	0.82 (0.35 to 2.01)		0.646		
Visualblur	1.79 (0.84 to 3.81)		0.129		
Nausea/vomiting	1.30 (0.60 to 2.78)		0.495		
Diplopia‡	2.07 (0.85 to 4.85)		0.098		
Tinnitus	1.32 (0.28 to 4.73)		0.687		
Eclipses	2.61 (0.83 to 7.62)		0.085		
Seizures	4.26 (0.96 to 18.92)		0.049		
	Mean A	Mean NA	P value	OR (95% CI)	P value
Age (years)	24.57	22.04	0.997		
BMI (kg/m <sup>2</sup> †)	25.72	28.09	0.061		
ICP (cmH20)	36.40	43.57	<b>0.042</b>		
TR D0 ( $\mu$ m)	483.72	796.69	<b>p&lt;0.001</b>	1.01 (1.01 to 1.02)	<b>0.001</b>
RNFL j0 ( $\mu$ m)	199.63	365.28	<b>p&lt;0.001</b>		
Delay§	40.43	71.69	0.136		

The bold values are the significant values ( $p < 0.05$ ).  
 \*Defined by a visual field impairment other than blind spot enlargement.  
 †Defined by an initial GCL at D0 lower than 1 mm<sup>3</sup>.  
 ‡By paralysis of the VI nerve.  
 §Delay between the first symptoms and the diagnosis.  
 BMI, body mass index; GCL, ganglion cell layer; ICP, intracranial pressure; IIH, idiopathic intracranial hypertension; mean A/NA, mean in the atrophy/non-atrophy group; RNFL D0, retinal nerve fibre layer thickness at diagnosis; TR D0, total peripapillary retinal thickness at diagnosis; VA $\leq$ 20/25, initial visual acuity less than or equal 20/25 on the Snellen scale; VF, visual field.

correlated with the presence of optic nerve atrophy at the final follow-up with an OR=19.12 (95% CI 3.92 to 111.37,  $p<0.001$ ).

The aetiology of IH did not correlate with the primary outcome. Idiopathic or secondary IH was not showing any risk of progression towards optic nerve atrophy. Initial visual acuity inferior or equal to 20/25 on the Snellen scale was also strongly correlated with final optic nerve atrophy with an OR=7.76 (95% CI 1.35 to 46.39,  $p=0.02$ ). Visual field damages were significantly correlated with optic nerve atrophy in univariate analysis with an OR=37.51 (95% CI 10.97 to 176.88,  $p<0.001$ ). However, they were not retained in the multivariate model. Some patients had an impaired GCL since the initial stage with a volume of less than 1 mm<sup>3</sup>. This impairment was a significant risk factor for optic nerve atrophy with an OR=18.25 (95% CI 1.94 to 416.59,  $p=0.021$ ).

Analyses of first symptoms were also performed to determine whether certain symptoms were potentially suggestive of severity and thus of progression to optic atrophy. No significant association was found.

### Relationship between OCT and primary endpoint in atrophic versus non-atrophic patients

Quantitative variables were analysed in relation to the primary outcome. The initial RNFL was significantly correlated with optic atrophy with a mean RNFL at 199.63  $\mu$ m in the 'non-atrophy' group and 365.28  $\mu$ m in the 'atrophy' group. Initial TR was also correlated with optic atrophy with a mean TR at 483.72  $\mu$ m in the 'non-atrophy' group and 796.69  $\mu$ m in the 'atrophy' group. However, in the multivariate model, only one of these two variables was retained by the analysis because they are highly dependent on each other. ICP and scleral canal size were significantly correlated with optic atrophy in univariate analysis but were not retained in the multivariate analysis due to a large amount of missing data.

### CONCLUSIONS

This study on 113 patients from a real-life setting identifies risk factors long-term optical nerve atrophy after an increased intracerebral pressure, independent from the underlying aetiology and using OCT.

Total peripapillary retinal thickness has been used to quantify initial papilloedema because it is a more reliable value for high-grade papilloedema and because it compares favourably with the clinical staging of Frisén.<sup>6</sup> Indeed, RNFL treatment algorithms often fails to provide a proper segmentation in high-grade papilloedema while total retinal thickness works more better.

Albrecht *et al* demonstrated that initial RNFL thickness is a predictor of RNFL loss over time in patients with IHH.<sup>11</sup> The similar study by Kabatas *et al* prospectively followed eyes with papilloedema due to IHH. Patients with optic atrophy had the following characteristics: higher cerebrospinal fluid opening pressure, higher grade of papilloedema, thicker mean peripapillary RNFL thickness, thinner GCL layer and severe visual field loss.<sup>12</sup> Our study confirms these findings in stasis papilloedema regardless of the underlying aetiology.

Older studies have already identified clinical risk factors for optic atrophy based on visual acuity impairment but without the use of OCT. They include the grade of papilloedema according to the Frisén classification, the presence of peripapillary haemorrhage and advanced age.<sup>7</sup> Initial visual acuity is impaired in 5%–17% of patients in the literature.<sup>13</sup> This clinical presentation is a major risk factor for visual pathway damage. A more recent study has also shown that the Frisén grade of papilloedema is also a risk factor for optic atrophy in the paediatric population.<sup>14</sup>

We chose to use OCT parameters as the primary outcome measure because it is an objective and reproducible criterion that reliably reflects anatomical optic loss. Regarding the functional consequences of optic atrophy, it has been demonstrated that visual acuity is generally preserved and is not the first visual function affected.<sup>15 16</sup> It is not a reproducible and discriminative criterion reflecting the occurrence of optic atrophy. Therefore, we did not select it as the primary outcome measure. Nevertheless, it remains an important evaluation criterion since there is still a risk of decreased visual acuity, as it was the case in 5% of our patients.

Visual field testing is a much better assessment of visual function in patients with optic atrophy. Optic atrophy can lead to visual field defects characterised by diffuse and unsystematic scotomas with a decrease in mean deviation. Because this is a retrospective study, most of the visual fields conducted were Goldman visual fields rather than automated visual fields due to the routine practices of the services. Furthermore, there were missing values of mean deviation, which prevented us from choosing it as the primary outcome measure. Because of this methodological difference, it is not possible to directly compare the data from Goldman visual fields with that of automated visual fields. However, it has been shown that RNFL thickness is strongly correlated with mean deviation in optic atrophy, regardless of the underlying causes,<sup>15</sup> confirming the relevance of analysing the final RNFL as a marker of optic atrophy occurrence. Future analyses are required to confirm the correlation between

final RNFL and visual field in cases of optic atrophy due to papilloedema.

Severe optic disc oedema with elevated ICP makes the optic disc highly vulnerable to ischaemia because of compression of the vessels within. There is an increased vascular resistance due to the compression of capillaries by swollen axons and accumulation of extracellular fluid in the oedema and venous stasis.<sup>17</sup> According to Miceli *et al*, the severity of papilloedema is not associated with age, race, gender or BMI in patients with IH but is significantly higher with elevated CSF opening pressure.<sup>18</sup> In this study, there was no observed correlation between BMI and optic atrophy, which aligns with the findings in Orcutt *et al*'s study, where no significant correlation was found in the idiopathic intracranial hypertension (IIH) subgroup.<sup>7</sup> On the other hand, a retrospective study of 414 patients found a tendency to loss of vision associated with a severe BMI (greater than 40 kg/m<sup>2</sup>) with an OR=1.4 (95% CI 1.03 to 1.91, p=0.03).<sup>19</sup>

Unilateral involvement represented 3.5% of our patients. This is a rare phenomenon but described in the literature as being around 4% in papilloedema.<sup>20</sup> One study suggests that asymmetric papilloedema stems from asymmetries in the bony optic canal that interfere with the flow of cerebrospinal fluid between the perioptic subarachnoid spaces.<sup>20</sup>

This study also found a strong association between the alteration of the initial GCL and the final optic atrophy. We used GCL volume instead of the thickness because we did not have access to thickness values at the inception of the study. Furthermore, both in our clinical practice and in the literature, we observe that GCL volume is a highly relevant metric for assessing the entire GCL layer, as it reflects a potential localised loss that could be missed if we were to rely solely on the average thickness value. Hence, we employed this data to evaluate the MGCL. This strong association between the alteration of the GCL and the final optic atrophy, which is consistent with the study by Marzoli *et al*, indicates that, in patients with IH, signs of optic neuropathy can be identified even in the presence of papilloedema.<sup>21</sup> Thus, OCT, which is already useful for quantifying papilloedema, may show retinal ganglion cell damage in an early phase of the disease.<sup>22</sup>

The sex ratio in our study in favour of females is explained by a preponderance of females in IHH and cerebral venous thrombosis with the important role of sex hormones.<sup>23 24</sup> However, male or female sex is neither a risk factor nor a protective factor for optic atrophy, which partly contradicts the Bruce *et al* study in which men with IHH were twice as likely as women to develop severe visual loss, but this study used visual acuity as the principal outcome.<sup>25</sup>

The size of the scleral canal usually measures about 1.5 mm in healthy patients. This cohort presents a larger size because of a higher cerebrospinal fluid pressure in the optic nerve sheath for patients with IH. It also appears to be moderately correlated with progression to optic atrophy.



OCT is a marker of treatment efficacy and disease progression in IH.<sup>26</sup> It is a quick and easy alternative to repeated lumbar punctures for monitoring patients with IH, and facilitates monitoring of disease progression and response to treatment. In addition, several studies have shown that the rise in ICP correlates with the hike in RNFL during the follow-up of these patients.<sup>27 28</sup>

However, this study shows some limitations. It is a retrospective study and some clinical data from the interview or clinical examination were not always specified, such as the presence of certain symptoms or peripapillary haemorrhages. Also, children were mostly excluded from the study because OCT was often impossible to perform due to lack of compliance with the examination. The prevalence of IH was low in our cohort because the more serious aetiologies (tumours, thromboses) are overestimated in connection with the region's reference neurosurgery department attached to our ophthalmology department. However, the aetiology of IH had no correlation with the primary outcome. Finally, non-significant relationship could be due to an underpowered assessment. For example, ICP and scleral canal size are significantly correlated with atrophy in univariate analysis but were not included in the multivariate analysis due to a large amount of missing data.

In conclusion, this study identified risk factors for optic atrophy in papilloedema. The initial grade of oedema is easily quantifiable with OCT and is an important reflection of the risk of optic suffering. The presence of an initial severe visual acuity drop, early GCL damage or peripapillary haemorrhages are also associated with progression to optic atrophy. It would then be interesting to follow up after the medical treatment those patients who show these characteristics.

**Acknowledgements** This article was the subject of Ruben Attia's thesis, but it has not yet been published to date. To my dear coauthors, a heartfelt thank you for your invaluable contribution.

**Contributors** Guarantor : RA. Realisation/acquisition of data/redaction/statistical analysis: RA. Conception: NS. Planning: TD. Interpretation of data: PT and J-PS. Data analysis: BA and SD. Reviewing/finalising the manuscript: RF and KM.

**Funding** The authors have not declared a specific grant for this research from any funding agency in the public, commercial or not-for-profit sectors.

**Competing interests** None declared.

**Patient and public involvement** Patients or the public were not involved in the design, or conduct, or reporting, or dissemination plans of our research.

**Patient consent for publication** Not applicable.

**Ethics approval** This study involves human participants and has been approved by the Ethics Committee of the French Society of Ophthalmology (IRB 00008855 Société Française d'Ophthalmologie IRB#1) because the committee did not find any challenge against the medical and scientific rules of ethics, as accepted in France.

**Provenance and peer review** Not commissioned; externally peer reviewed.

**Data availability statement** Data are available on reasonable request.

**Open access** This is an open access article distributed in accordance with the Creative Commons Attribution Non Commercial (CC BY-NC 4.0) license, which permits others to distribute, remix, adapt, build upon this work non-commercially, and license their derivative works on different terms, provided the original work is properly cited, appropriate credit is given, any changes made indicated, and the use is non-commercial. See: <http://creativecommons.org/licenses/by-nc/4.0/>.

#### ORCID iDs

Ruben Attia <http://orcid.org/0000-0001-6882-7555>

Thierry David <http://orcid.org/0000-0002-7192-1523>

#### REFERENCES

- Corbett JJ, Savino PJ, Thompson HS, *et al*. Visual loss in pseudotumor cerebri. follow-up of 57 patients from five to 41 years and a profile of 14 patients with permanent severe visual loss. *Arch Neurol* 1982;39:461–74.
- Kilgore KP, Lee MS, Leavitt JA, *et al*. Re-evaluating the incidence of idiopathic intracranial hypertension in an era of increasing obesity. *Ophthalmology* 2017;124:697–700.
- Akhter A, Schulz L, Inger HE, *et al*. Current indications for management options in pseudotumor cerebri. *Neurol Clin* 2022;40:391–404.
- Shields LBE, Shields CB, Yao TL, *et al*. Endovascular treatment for venous sinus stenosis in idiopathic intracranial hypertension: an observational study of clinical indications, surgical technique, and long-term outcomes. *World Neurosurg* 2019;121:e165–71.
- Frisén L. Swelling of the optic nerve head: a staging scheme. *J Neurol Neurosurg Psychiatry* 1982;45:13–8.
- Scott CJ, Kardon RH, Lee AG, *et al*. Diagnosis and grading of papilledema in patients with raised intracranial pressure using optical coherence tomography vs clinical expert assessment using a clinical staging scale. *Arch Ophthalmol* 2010;128:705–11.
- Orcutt JC, Page NG, Sanders MD. Factors affecting visual loss in benign intracranial hypertension. *Ophthalmology* 1984;91:1303–12.
- Wang J-K, Kardon RH, Kupersmith MJ, *et al*. Automated quantification of volumetric optic disc swelling in papilledema using spectral-domain optical coherence tomography. *Invest Ophthalmol Vis Sci* 2012;53:4069–75.
- Dreesbach M, Joachimsen L, Kuchlin S, *et al*. Optic nerve head volumetry by optical coherence tomography in papilledema related to idiopathic intracranial hypertension. *Transl Vis Sci Technol* 2020;9:24.
- Friedman DI, Liu GT, Digre KB. Revised diagnostic criteria for the pseudotumor cerebri syndrome in adults and children. *Neurology* 2013;81:1159–65.
- Albrecht P, Blasberg C, Ringelstein M, *et al*. Optical coherence tomography for the diagnosis and monitoring of idiopathic intracranial hypertension. *J Neurol* 2017;264:1370–80.
- Kabatas N, Eren Y, Nalcacioglu P, *et al*. Management of the regression of papilledema with regional axon loss in idiopathic intracranial hypertension patients. *Int Ophthalmol* 2021;41:1467–77.
- Boddie HG, Banna M, Bradley WG. Benign intracranial hypertension. a survey of the clinical and radiological features, and long-term prognosis. *Brain* 1974;97:313–26.
- Gospe SM, Bhatti MT, El-Dairi MA. Anatomic and visual function outcomes in paediatric idiopathic intracranial hypertension. *Br J Ophthalmol* 2016;100:505–9.
- Soltan-Sanjari M, Parvaresh M-M, Maleki A, *et al*. Correlation between retinal nerve fiber layer thickness by optical coherence tomography and perimetric parameters in optic atrophy. *J Ophthalmic Vis Res* 2008;3:91–4.
- Markey KA, Mollan SP, Jensen RH, *et al*. Understanding idiopathic intracranial hypertension: mechanisms, management, and future directions. *Lancet Neurol* 2016;15:78–91.
- Hayreh SS. Pathogenesis of optic disc edema in raised intracranial pressure. *Prog Retin Eye Res* 2016;50:108–44.
- Micieli JA, Gorham JP, Bruce BB, *et al*. Clinical and demographic differences between idiopathic intracranial hypertension patients with mild and severe papilledema. *Taiwan J Ophthalmol* 2021;11:53–6.
- Szewka AJ, Bruce BB, Newman NJ, *et al*. Idiopathic intracranial hypertension: relation between obesity and visual outcomes. *J Neuroophthalmol* 2013;33:4–8.
- Bidot S, Bruce BB, Saindane AM, *et al*. Asymmetric papilledema in idiopathic intracranial hypertension. *J Neuroophthalmol* 2015;35:31–6.
- Marzoli SB, Ciasca P, Curone M, *et al*. Quantitative analysis of optic nerve damage in idiopathic intracranial hypertension (IH) at diagnosis. *Neurol Sci* 2013;34 Suppl 1:S143–5.
- Athappilly G, Garcia-Basterra I, Machado-Miller F, *et al*. Ganglion cell complex analysis as a potential indicator of early neuronal loss in idiopathic intracranial hypertension. *Neuroophthalmology* 2019;43:10–7.
- Thurtell MJ. Idiopathic intracranial hypertension. *CONTINUUM (Minneapolis)* 2019;25:1289–309.

- 24 Zuurbier SM, Middeldorp S, Stam J, *et al.* Sex differences in cerebral venous thrombosis: a systematic analysis of a shift over time. *Int J Stroke* 2016;11:164–70.
- 25 Bruce BB, Kedar S, Van Stavern GP, *et al.* Idiopathic intracranial hypertension in men. *Neurology* 2009;72:304–9.
- 26 Kaufhold F, Kadas EM, Schmidt C, *et al.* Optic nerve head quantification in idiopathic intracranial hypertension by spectral domain OCT. *PLoS One* 2012;7:e36965.
- 27 Skau M, Yri H, Sander B, *et al.* Diagnostic value of optical coherence tomography for intracranial pressure in idiopathic intracranial hypertension. *Graefes Arch Clin Exp Ophthalmol* 2013;251:567–74.
- 28 Patel MD, Malhotra K, Shirazi Z, *et al.* Methods for quantifying optic disc volume and peripapillary deflection volume using radial optical coherence tomography scans and association with intracranial pressure. *Front Neurol* 2019;10:798.